

# Cone Dysfunction in Patients With Late-Onset Cone Dystrophy and Age-Related Macular Degeneration

Markus Ladewig, MD; Hannelore Kraus; Michael H. Foerster, MD; Ulrich Kellner, MD

**Objectives:** To determine the clinical and functional findings in patients with late-onset cone dystrophy (LOCD) (after the age of 50 years), which is rare; and to compare them with those of patients with age-related macular degeneration (AMD).

**Methods:** Eleven LOCD patients underwent ophthalmologic and electroretinographic examinations. Full-field electroretinograms were recorded according to the International Society for Clinical Electrophysiology of Vision standard. The results were compared with those of a group of 20 AMD patients and a group of 23 age-related control subjects.

**Results:** There was no difference between LOCD and AMD patients regarding the severity of visual acuity loss, color vision deficiencies, and central visual field defects. Alterations of the posterior pole were present in

all LOCD and AMD patients. In contrast to the AMD group, all LOCD patients did not show drusen and 6 of the 11 LOCD patients displayed temporal optic disc pallor. The electroretinogram revealed the major functional difference, with severe reduction of cone-mediated responses and moderate reduction of rod-mediated responses in LOCD patients. Unexpectedly, the 30-Hz flicker amplitude was reduced in AMD patients compared with healthy controls.

**Conclusions:** Late-onset cone dystrophy and AMD have several features in common. In elderly patients with progressive visual loss and without drusen, LOCD should be considered. The electroretinographic results in a small group of AMD patients indicate a generalized cone dysfunction.

*Arch Ophthalmol.* 2003;121:1557-1561

**T**HE PROGRESSIVE cone dystrophies are a heterogeneous group of inherited retinal dystrophies primarily characterized by an impaired function of the retinal cones. Characteristic symptoms are photophobia, progressive visual loss, defects of color vision up to monochromatism, and relative or absolute central scotomata.<sup>1-5</sup> Ophthalmoscopic findings range from normal to unspecific retinal pigment irregularities, to bull's eye maculopathy.<sup>1,3</sup> Clinical signs of cone dystrophies may develop progressively during all decades of life.<sup>4</sup> In most patients, the first symptoms occur between the first and the third decade of life. Later onset, in the fourth<sup>2,6</sup> or even after the sixth decade, is rare.<sup>1,5,6</sup> Therefore, the diagnosis of cone dystrophy is not often considered in older patients. In addition, age-related morphological changes, such as pigment irregularities and drusen, can mask the correct diagnosis. Elderly patients show an increased frequency of other age-related disorders, such as age-related

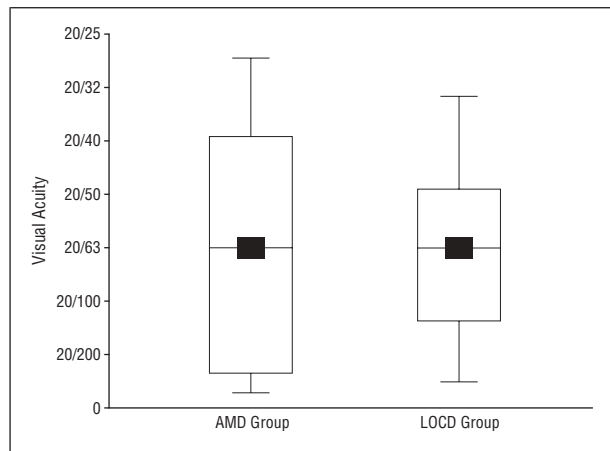
macular degeneration (AMD), manifesting with similar signs. Paraneoplastic retinopathy<sup>7</sup> and digitalis intoxication<sup>8</sup> need to be considered as other possible differential diagnoses.

This study investigates the clinical and electrophysiological features in patients with the onset of cone dystrophy after the age of 50 years (late-onset cone dystrophy [LOCD]). The most frequent macular disorder in elderly patients is AMD, and some LOCD patients were referred with the diagnosis of AMD. Therefore, the LOCD group was compared with a group of patients with AMD.

## METHODS

For this study, 11 patients who displayed the first signs of cone dystrophy after the age of 50 years were selected from a series of 160 patients with cone dystrophy.<sup>5</sup> Patients unable to determine the exact onset of their symptoms were not included in this study. Their mean  $\pm$  SD age at the time of the investigation was  $65 \pm 10$  (range, 52-80) years. Seven patients were women and 4 were men.

From the Department of Ophthalmology, Universitäts-Klinikum Benjamin Franklin, Freie Universität Berlin, Berlin, Germany. The authors have no relevant financial interest in this article.



**Figure 1.** The range of visual acuity in the age-related macular degeneration (AMD) and late-onset cone dystrophy (LOCD) groups. Black squares indicate mean values; box plots, 25% to 50% quantiles; horizontal lines inside the boxes, medians; and vertical lines, total range of visual acuity values.

The LOCD patients were compared with a group of AMD patients and a healthy control group; the minimum age for all groups was 50 years. Patients with generalized disorders possibly affecting the eyes (diabetes mellitus or metastatic cancer) were excluded from either the AMD or the control group. The AMD group consisted of 20 patients (9 women and 11 men), and their mean  $\pm$ SD age was  $70 \pm 9$  (range, 54-89) years. All AMD patients had drusen. Some patients had a small ( $<1$  disc diameter) choroidal neovascularization (CNV) without a substantial amount of subretinal fluid or hemorrhage, but most had pigment epithelial irregularities or atrophic retinal degeneration.

The control group included only persons without known eye diseases or persons who did not undergo ocular surgery in the investigated eye; their mean  $\pm$ SD age was  $62 \pm 7$  (range, 51-73) years. A visual acuity of 20/20 was required, and refractive errors were limited to  $\pm 2$  diopters (D). In addition, the following findings had to be normal: biomicroscopy of the anterior and posterior segments, the Goldmann visual field, ocular pressure, and color vision.

Examinations in this study were performed after informed consent was given according to the Declaration of Helsinki. All patients and all controls underwent a detailed ophthalmologic examination, including determination of visual acuity and refraction, measurement of the intraocular pressure, a slitlamp examination of the anterior segment, and a stereoscopic retinal examination. Color vision was evaluated with the Lanthony desaturated Panel D15 test (Luneau Ophthalmologie, Chartres, France). The visual field was determined by the kinetic Goldmann perimeter.

Full-field electroretinograms (ERGs) were recorded for all patients and controls according to the International Society for Clinical Electrophysiology of Vision standard,<sup>9</sup> as reported in detail previously.<sup>10</sup> For ERG recording, a commercial recording unit (Nicolet Spirit; Nicolet, Madison, Wis) in combination with a full-field stimulator (Nicolet Ganzfeld; Nicolet) was used. Recordings were performed without averaging, using a Jet contact lens electrode and maximal dilated pupils (dilated using 2.5% phenylephrine hydrochloride and 0.5% tropicamide). The stimulus duration was 0.1 milliseconds. Following 30 minutes of dark adaptation, 4 stimuli with increasing intensity (maximum light intensity, 10 candelas [ $\text{cd}$ ]  $\cdot$   $\text{s}/\text{m}^2$ ) were used for recordings in the dark. Light-adapted recordings were performed after 10 minutes of light adaptation in the presence of white background light (30  $\text{cd}/\text{m}^2$ ) with white stimuli of maximum light intensity. For all single-flash stimuli, the amplitudes and implicit times of the a and b waves were measured, along with

the amplitude and implicit time of the 30-Hz flicker response. Statistics were analyzed with the Wilcoxon rank sum/Kruskal-Wallis nonparametric test, and data were considered significant at  $P < .05$ .

## RESULTS

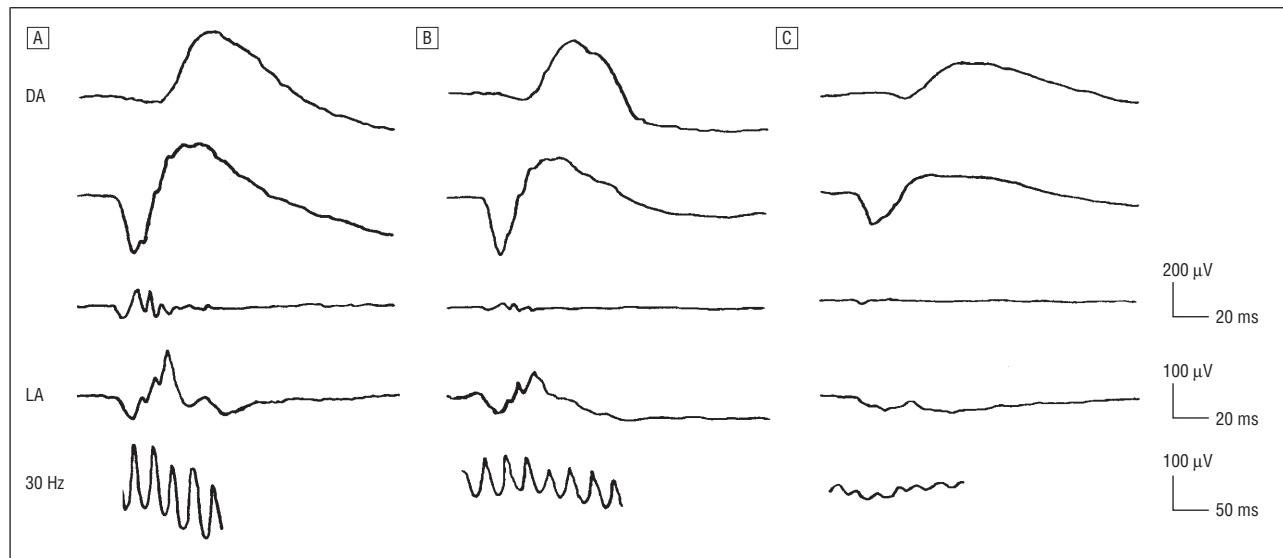
The patients in the LOCD group were investigated at a mean  $\pm$ SD age of  $65 \pm 10$  (range, 52-80) years, but the onset of symptoms was noted at a mean  $\pm$ SD age of  $56 \pm 6$  (range, 50-66) years by the patients. During onset, reading difficulties and visual loss were the most important initial signs. Although almost all patients described color vision defects, only a few found them bothersome and reported them without questioning. Three LOCD patients complained spontaneously of photophobia.

The first investigation of the AMD group was at a mean  $\pm$ SD patient age of  $70 \pm 9$  (range, 54-89) years, and initial symptoms occurred at a mean  $\pm$ SD age of  $67 \pm 11$  (range, 50-73) years. Initial signs during onset were metamorphopsia and visual loss; no AMD patient complained spontaneously about photophobia or color vision defects.

The anterior segment was normal for age in all LOCD and AMD patients. Changes at the posterior pole were present in most LOCD and all AMD group patients. The ophthalmoscopic findings were symmetric for both eyes, except for the CNV in AMD patients. Six patients in the LOCD group displayed a pale optic disc, compared with no patients in the AMD group. In the LOCD group, one patient had a bull's eye maculopathy and the other patients had findings ranging from a normal fundus appearance to minor foveal changes (distinctive areas of atrophy of the pigment epithelium and the choriocapillaris of the posterior pole). Drusen were seen in all patients of the AMD group. Pigment epithelial atrophy was present in 12 AMD patients, and CNV was present in the remaining 8 AMD patients. The retinal periphery was normal in all AMD patients and most LOCD patients. In one LOCD patient, moderate bone spicules could be observed in the midperiphery.

Visual acuity in the LOCD and the AMD groups was reduced to a mean of 20/63 in the eye with the lower visual acuity at the first investigation (**Figure 1**). All patients in both groups reported a progressive reduction in visual acuity. The history of progressive vision loss displayed a variable course, particularly in the LOCD group. Whereas some patients reported marked reduction of visual acuity within a few months, in others, the progression was much slower. Most of the AMD patients had a gradual visual reduction for a few months up to several years. The LOCD patients had a mean  $\pm$ SD refractive correction of  $0.25 \pm 3.30$  (range,  $-5.0$  to  $6.0$ ) D. Six patients were hyperopic, 3 were myopic, and 2 were emmetropic; 6 patients had an astigmatism. One patient was pseudophakic in both eyes. The mean  $\pm$ SD refractive correction in the AMD group was  $0.68 \pm 2.60$  (range,  $-6.5$  to  $5.0$ ) D. Twelve patients were hyperopic, 4 were myopic, and 4 were emmetropic. An astigmatism existed in 14 patients.

None of the LOCD patients had normal color vision. There was no correlation between visual acuity and



**Figure 2.** Characteristic full-field electroretinographic responses for a control proband (A), a patient with age-related macular degeneration (B), and a patient with late-onset cone dystrophy (C). After dark adaptation (DA), the rod responses (first row), the mixed rod-cone responses (second row), and the oscillatory potentials (third row) were recorded. After light adaptation (LA), the single-flash cone responses (fourth row) and the 30-Hz flicker responses (bottom row) were recorded.

### Summary of Electroretinographic Results

Variable	Control Group*	AMD Group*	P Value for AMD Group vs Control Group	LOCD Group*	P Value for LOCD Group vs AMD Group
After dark adaptation					
Rod response					
a-Wave amplitude, $\mu\text{V}$	53 $\pm$ 22	38 $\pm$ 21	<.02	21 $\pm$ 23	<.05
b-Wave amplitude, $\mu\text{V}$	416 $\pm$ 55	391 $\pm$ 95	.27	170 $\pm$ 136	<.001
Rod-cone response					
a-Wave amplitude, $\mu\text{V}$	438 $\pm$ 70	368 $\pm$ 108	<.02	202 $\pm$ 136	<.004
b-Wave amplitude, $\mu\text{V}$	684 $\pm$ 86	624 $\pm$ 120	.13	307 $\pm$ 223	<.001
b-Wave implicit time, ms	47.0 $\pm$ 4.2	48.0 $\pm$ 4.5	.49	50.0 $\pm$ 5.5	.61
After light adaptation					
Cone response					
a-Wave amplitude, $\mu\text{V}$	82 $\pm$ 18	60 $\pm$ 20	<.001	36 $\pm$ 27	<.02
b-Wave amplitude, $\mu\text{V}$	230 $\pm$ 39	194 $\pm$ 50	.08	76 $\pm$ 62	<.001
b-Wave implicit time, ms	32.1 $\pm$ 2.1	32.6 $\pm$ 1.2	.41	35.1 $\pm$ 1.7	<.001
30-Hz flicker response					
Amplitude, $\mu\text{V}$	206 $\pm$ 25	153 $\pm$ 39	<.001	72 $\pm$ 56	<.003
Implicit time, ms	29.1 $\pm$ 1.4	30.0 $\pm$ 1.8	.16	31.5 $\pm$ 1.5	<.03

Abbreviations: AMD, age-related macular degeneration; LOCD, late-onset cone dystrophy.

\*Data are given as mean  $\pm$  1 SD.

color vision defects. Only one AMD patient had normal color vision. In the AMD group, color vision defects were more severe with increased reduction of visual acuity. The results of visual field testing in the LOCD patients included normal findings, moderate concentric narrowing of the outer isopters, paracentral scotomata, and central scotomata. Patients with a central scotoma had a distinctly worse visual acuity compared with patients with other visual field limitations. On the other hand, a central scotoma could not be detected in all LOCD patients with a severely reduced visual acuity. In the AMD group, no narrowing in the outer isopters was detected; however, almost all patients revealed a central or paracentral scotoma. All AMD patients with a central scotoma had a severely reduced visual acuity.

As for the other tests, during evaluation of the full-field ERG, the intraocular differences of each patient remained within the normal range. Therefore, for each patient, only the eye with the lower amplitudes was included in further evaluations. In **Figure 2**, typical ERG recordings for all groups are shown; the **Table** gives an overview of all ERG results. Two LOCD patients did not have measurable potentials at any stimulus setting, whereas all AMD patients had measurable potentials at all recording conditions.

After dark adaptation, LOCD patients had significantly reduced a- and b-wave amplitudes for the rod response and the mixed cone-rod response. The b-wave implicit time for the mixed cone-rod response at maximum stimulus intensity was the single variable that fell within

the normal range in the LOCD group. The AMD patients had normal b-wave amplitudes and implicit times. The a-wave amplitudes, however, were reduced for the rod response and the mixed cone-rod response, which may be indicative of a mild photoreceptor dysfunction.

After light adaptation, the a- and b-wave amplitudes of the single-flash cone response were severely reduced in LOCD patients and the b-wave implicit time was markedly prolonged. In contrast, in AMD patients, the b-wave implicit time was well within the normal range. The b-wave amplitude was slightly lower compared with that of controls, but the difference was not significant. Only the a-wave amplitudes were significantly reduced for AMD patients.

The 30-Hz flicker response was significantly reduced in the LOCD patients. The 30-Hz flicker implicit time was significantly prolonged, although the prolongation was slightly less compared with that of the single-flash response. Unexpectedly, there was a significant reduction of the 30-Hz flicker response of the AMD patients compared with that of the controls; this was the largest difference of all variables comparing AMD patients with controls. In contrast to the LOCD patients, there was no significant difference in the implicit time of the 30-Hz flicker response between the controls and the AMD patients.

#### COMMENT

From a large series of patients with cone and cone-rod dystrophies, 11 who first became aware of progressive binocular visual acuity loss after the age of 50 years were selected. Photophobia was an additional subjective symptom in several of these 11 patients. On ophthalmoscopic examination, either a normal fundus or alterations of variable severity were detected. A functional evaluation revealed visual acuity loss, color vision deficits, and visual field defects. The full-field ERG cone responses after light adaptation, particularly the 30-Hz flicker responses, were more reduced and delayed compared with the dark-adapted responses. These ERG findings indicate a predominant cone pathway dysfunction and a less severe rod pathway dysfunction. In summary, the morphological and functional characteristics and the variability of the clinical course of these 11 patients are comparable to the findings in the larger group of patients with progressive cone dysfunction and to characteristics reported for cone dystrophy in the literature.<sup>1,5</sup> We chose LOCD to describe this subgroup because only age separated this group from younger patients with cone dystrophy.

There are only a few reports of patients with LOCD. Rowe et al<sup>6</sup> described 6 cases, and Krill et al<sup>1</sup> described 4 cases, of this disorder. In the present study, family history suggested an inherited disorder only in one LOCD patient. Rowe et al described 1 of 6 patients with LOCD with a possible familial inheritance. In younger patients, it has been shown that cone dystrophy summarizes a heterogeneous group of disorders with autosomal dominant, autosomal recessive, or X-linked inheritance.<sup>1,2,4,5,11-13</sup> Mutations in various genes have been reported to be associated with progressive cone dystrophy, and additional gene loci have been detected.<sup>14</sup> It has

to be expected that LOCD also summarizes a heterogeneous group of genetic defects. Molecular genetic and familial studies will be necessary to extend our understanding of the pathophysiologic features; however, these are difficult to conduct for disorders with a late onset and a rare occurrence.

In LOCD patients, and in cone dystrophy in other age groups, the fundus appearance on ophthalmoscopy cannot alone establish the diagnosis.<sup>5,15</sup> Most patients had unspecific pigment epithelial defects, one had a bull's eye maculopathy, and one had peripheral bone spicules. Two patients had normal morphological fundus findings. Rowe et al<sup>6</sup> described 2 LOCD patients with a normal posterior pole; the other patients showed mild changes in the pigment epithelium. The variability of morphological alterations is comparable to findings in younger patients with cone dystrophy.<sup>1,4,5</sup> Drusen were not seen in any LOCD patient.

In an elderly population, it is important to exclude a possible differential diagnosis, which may be as frequent as LOCD. Acquired cone dystrophies are rare, and can occur in connection with drugs<sup>8</sup> or as paraneoplastic retinopathies.<sup>7</sup> Therefore, a careful differential diagnosis is mandatory, because retinal dysfunction may be an early sign of cancer or withdrawal of a drug may reduce the symptoms and stop progression. In the present study, the medical history was negative concerning potentially retinotoxic drugs, cancer, and secondary causes for retinal dysfunction (infection or trauma). It is impossible to exclude whether an undiagnosed vascular dysfunction may have had influence on retinal function; however, no vascular abnormalities were detected in the LOCD patients and severe generalized vascular disease was not reported by the patients.

The most frequent differential diagnoses in this age group, however, are age-related maculopathy and AMD. Patients with AMD were included in this study because they have several symptoms in common with LOCD patients. The AMD patients selected for this study had drusen, geographic pigment epithelial atrophy, or small CNVs with limited surrounding exudate. Patients who displayed severe disciform scarring, subretinal hemorrhaging, marked exudative disease, or progressed geographic atrophy were not included; because of their clinical signs, they are unlikely to be misdiagnosed patients with LOCD and secondary retinal changes will influence retinal function testing.

In LOCD and AMD patients, the first sign of the disease was loss of visual acuity, noted either as a problem with reading or while driving. The age of onset was lower in LOCD patients, but a large variability was seen in both groups. Visual loss was progressive in both disorders, and visual acuity was reduced to a similar extent. No difference was found concerning the refractive error. Unspecific color vision deficits were present in nearly all patients in both groups. Central visual field defects were found in both groups; however, as expected, peripheral field defects were not detected in the AMD group. The ophthalmoscopic examination gave the first indication that there is a distinct difference between LOCD and AMD patients. Although pigment irregularities were observed in most of the patients in both groups, drusen were



limited to patients with AMD. This may not be an exclusive diagnostic criterion, because it cannot be excluded that some elderly patient with LOCD may also develop drusen because of age-related pigment epithelial changes. Pallor of the optic disc is not uncommon in patients with cone dystrophies, and was seen in 6 of the 11 LOCD patients but not in any AMD patient.

The major functional difference between LOCD and AMD patients was demonstrated in the full-field ERG. In LOCD patients, the b-wave implicit time at maximum stimulus intensity after dark adaptation was the single variable within the age-related normal range. For all other ERG variables, amplitudes were markedly reduced and implicit times were delayed. In the AMD group, all amplitudes were lower than normal; however, the difference was significant only for a-wave amplitudes and the 30-Hz flicker response. There was no significant delay of the single-flash b-wave or 30-Hz flicker response.

The full-field ERG results in LOCD patients define them as having a form of cone dystrophy. Although the real onset of a disease remains unknown and the term *late onset*, therefore, is dependent on its definition, the patients in this series and those described by Rowe et al<sup>6</sup> and Krill et al<sup>1</sup> indicate that LOCD is a possible differential diagnosis in elderly patients with progressive visual dysfunction. Patients older than 50 years with progressive visual loss, with color vision deficits, and without drusen should especially undergo a detailed ERG examination. Despite the lack of specific treatment options, missing LOCD may have consequences for the patient in regard to counseling on progression, optimal low-vision aids, and affection of other family members. However, it is important for our understanding of the pathophysiologic processes underlying visual loss in elderly patients to define exactly disorders that may have similarities to AMD.

An unexpected finding in the present study was alterations of the full-field ERG in AMD patients. The macular area is small and contains about 5% of the retinal cones. Therefore, macular disorders usually go along with normal full-field ERG findings. In fact, the difficulty in detecting macular pathological features with the full-field ERG was the major reason to develop refined ERG methods, such as the pattern and multifocal ERG. The marked reduction of the 30-Hz flicker amplitude in AMD patients indicates an involvement of a larger retinal area than the macula. In addition, the difference in the time course of the 30-Hz flicker response in AMD and LOCD patients may be based on different retinal pathological features.

Previous reports on ERGs in AMD patients gave controversial results. For patients with AMD, no difference in ERG responses was detected compared with those of healthy controls in some studies,<sup>16</sup> whereas reduced amplitudes for cone- and rod-mediated responses, but a normal flicker response, were seen in others.<sup>17</sup> In patients with age-related maculopathy, Falsini et al<sup>18</sup> reported reduced flicker sensitivity in focal ERG recordings. An abnormal function of foveal cones was demonstrated in the fellow eyes of patients with unilateral CNVs in AMD.<sup>19</sup> In the latter study, the implicit times were delayed, but the amplitude reduction was small. These findings are

supported by a multifocal ERG evaluation of early AMD, which revealed delayed implicit times and reduced amplitudes.<sup>20</sup> Compared with the frequency of AMD, only a few AMD patients were included in this study. Therefore, caution must be used in generalizing the ERG findings in this study to all AMD patients. However, no specific selection criterion was used for these patients: a series of consecutive AMD patients who fit the inclusion criteria were asked to participate in this study. The controversial results in the literature and the findings in the present study request further analysis of the full-field ERG in AMD patients.

Submitted for publication December 31, 2002; final revision received May 20, 2003; accepted June 9, 2003.

Corresponding author: Ulrich Kellner, MD, Department of Ophthalmology, Universitäts-Klinikum Benjamin Franklin, Freie Universität Berlin, Hindenburgdamm 30, 12200 Berlin, Germany (e-mail: kellneru@zedat.fu-berlin.de).

## REFERENCES

1. Krill AE, Deutman AF, Fishman M. The cone degenerations. *Doc Ophthalmol*. 1973; 35:1-80.
2. Francois J, de Rouck A, Verriest G, de Laey JJ, Cambie E. Progressive generalized cone dysfunction. *Ophthalmologica*. 1974;169:255-284.
3. Kellner U, Kleine-Hartlage P, Foerster MH. Cone dystrophies: clinical and electrophysiological findings. *Ger J Ophthalmol*. 1992;1:105-109.
4. Weleber R, Eisner A. Cone degeneration ("bull's-eye dystrophies") and color vision defects. In: Newsome DA, ed. *Retinal Dystrophies and Degenerations*. New York, NY: Raven Press; 1988:233-256.
5. Kellner U. Die progressiven Zapfendystrophien. Stuttgart, Germany: Enke; 1996. Bücherei des Augenarztes Series; vol 135.
6. Rowe SE, Trobe JD, Sieving PA. Idiopathic photoreceptor dysfunction causes unexplained visual acuity loss in later adulthood. *Ophthalmology*. 1990;97:1632-1637.
7. Cogan DG, Kuwabara T, Currie J, Kattah J. Paraneoplastic Retinopathie unter dem klinischen Bild einer Zapfendystrophie mit Achromatopsie. *Klin Monatsbl Augenheilkd*. 1990;197:156-158.
8. Madreperla SA, Johnson MA, Nakatani K. Electrophysiologic and electroretinographic evidence for photoreceptor dysfunction as a toxic effect of digoxin. *Arch Ophthalmol*. 1994;112:807-812.
9. Marmor MF. An updated standard for clinical electrophysiology. *Arch Ophthalmol*. 1995;113:1375-1376.
10. Kellner U, Kraus H, Heimann H, Helbig H, Bornfeld N, Foerster MF. Electrophysiological evaluation of visual loss in Muller cell sheen dystrophy. *Br J Ophthalmol*. 1998;82:650-654.
11. Szyk JP, Fishman GA, Alexander KR, Peachey N, Derlacki DJ. Clinical subtypes of cone-rod dystrophy. *Arch Ophthalmol*. 1993;111:781-788.
12. Ripps H, Noble KG, Greenstein VC, Siegel IM, Carr RE. Progressive cone dystrophy. *Trans Am Ophthalmol Soc*. 1987;85:82-100.
13. Jacobson DM, Thompson HS, Bartley JA. X-linked progressive cone dystrophy: clinical characteristics of affected males and female carriers. *Ophthalmology*. 1989;96:885-895.
14. RetNet. Genes causing retinal disease. Available at: <http://www.sph.uth.tmc.edu/RetNet/>. Accessed April 24, 2003.
15. Kellner U, Ladewig M, Heinrich C. *Hereditary Retinal Dystrophies* [book on CD-ROM]. Stuttgart, Germany: Thieme; 2000.
16. Sunness JS, Massof RW, Johnson MA, Finkelstein D, Fine SL. Peripheral retinal function in age-related macular degeneration. *Arch Ophthalmol*. 1985;103:811-816.
17. Walter P, Widder RA, Luke C, Königfeld P, Brunner R. Electrophysiological abnormalities in age-related macular degeneration. *Graefes Arch Clin Exp Ophthalmol*. 1999;237:962-968.
18. Falsini B, Serrao S, Fadda A, et al. Focal electroretinograms and fundus appearance in nonexudative age-related macular degeneration: quantitative relationship between retinal morphology and function. *Graefes Arch Clin Exp Ophthalmol*. 1999;237:193-200.
19. Sandberg MA, Miller S, Gaudio AR. Foveal cone ERGs in fellow eyes of patients with unilateral neovascular age-related macular degeneration. *Invest Ophthalmol Vis Sci*. 1993;34:3477-3480.
20. Li J, Tso MO, Lam TT. Reduced amplitude and delayed latency in foveal response of multifocal electroretinogram in early age related macular degeneration. *Br J Ophthalmol*. 2001;85:287-290.