

RDS/peripherin gene mutations are frequent causes of central retinal dystrophies

Susanne Kohl, Margot Christ-Adler, Eckart Apfelstedt-Sylla, Ulrich Kellner, Anja Eckstein, Eberhart Zrenner, Bernd Wissinger

Abstract

Patients from 76 independent families with various forms of mostly central retinal dystrophies were screened for mutations in the RDS/peripherin gene by means of SSCP analysis and direct DNA sequencing. Two nonsense mutations (Gln239Ter, Tyr285Ter), five missense mutations (Arg172Trp, Lys197Glu, Gly208Asp, Trp246Arg, Ser289Leu), and one single base insertion (Gly208insG), heterozygous in all cases, were detected. Only one of these mutations, Arg172Trp, has been reported previously. Cosegregation of the mutation with the disease phenotype could be established in selected families. Other missense mutations were excluded from a panel of 55-75 control subjects. The patients showed remarkable variation in phenotype and disease expression not only between cases with different mutations but also between affected members of the same family. This study indicates that RDS/peripherin mutations are a frequent cause of various types of central retinal dystrophies and that the RDS/peripherin gene exhibits a broad spectrum of allelic mutations. Comparative analysis of known mutations allowed us to hypothesise that the deleterious effect of RDS/peripherin gene mutations is the result of different molecular mechanisms.

(*J Med Genet* 1997;34:620-626)

Keywords: RDS/peripherin; retinal dystrophies; mutation analysis

The RDS (retinal degeneration slow)/peripherin gene encodes a disc membrane associated glycoprotein in vertebrate photoreceptor outer segments. It has been shown that the RDS/peripherin polypeptide is preferentially located at the rim of the disc membranes and a role in the structural organisation of disc folding and stacking has been proposed.^{1,2} On heterologous expression, RDS/peripherin forms stable homo-oligomers or hetero-oligomeric structures with ROM1, another structurally related disc membrane protein.^{3,4} Whereas RDS/peripherin is expressed in rod as well as in cone photoreceptors, ROM1 expression is restricted to rods.^{3,5} It is not yet known whether a functional homologue of ROM1 exists in cone photoreceptors.

The role of RDS/peripherin in retinal disease was primarily established in the *rd*s (retinal

degeneration slow) mutant mouse, a semi-dominant inherited form of retinal degeneration characterised by shortened photoreceptor outer segments, progressive photoreceptor loss, and massive accumulation of cell debris at the level of the retinal pigment epithelium.^{6,7} It has been shown that a 9.2 kb insertion into the mouse RDS/peripherin gene is responsible for the retinal degeneration phenotype in the *rd*s mouse.^{8,9}

The human RDS/peripherin gene has been cloned and localised on human chromosome 6 in the vicinity of a locus for autosomal dominant inherited retinitis pigmentosa (now called RP7).^{10,11} Consequently, analysis of the human RDS/peripherin gene in patients with retinitis pigmentosa led to the identification of mutations segregating with the disease phenotype in an autosomal dominant fashion.^{12,13} Analysing a selection of patients with several kinds of retinal degeneration, Wells *et al*.¹⁴ found mutations not only in retinitis pigmentosa patients but also in patients suffering from cone dystrophy, pattern dystrophy, and macular degeneration. This phenotypic variation is not only caused by allelic mutations in the RDS/peripherin gene but expression of the disease is even variable within families,¹⁵ a phenomenon now acknowledged to be characteristic of RDS/peripherin gene mutations.

Up to now more than three dozen different mutations in the RDS/peripherin gene have been reported, mostly in pedigrees displaying autosomal dominant inheritance. In some cases, however, digenic inheritance involving both the RDS/peripherin and the ROM1 loci has been suggested.¹⁶

We have undertaken a molecular genetic analysis of patients with various forms of central retinal dystrophy in order to determine the prevalence of RDS/peripherin mutations in this group and to contribute to a more complete record of the RDS/peripherin gene mutation spectrum.

Subjects and methods

PATIENTS AND FAMILIES

Patients were seen at the Universitäts-Augenklinik Tübingen or the Augenklinik at the Universitätsklinikum Benjamin Franklin Berlin. Ophthalmological examination included visual acuity and visual field measurement, fundus examination, colour vision testing, dark adaptation curves, ERG recordings, and fluorescein angiography. Inclusion criteria were central or generalised tapetoretinal dystrophy with intrafamilial variability

Molekulargenetisches Labor, Universitäts-Augenklinik Tübingen, Auf der Morgenstelle 15, D-72076 Tübingen, Germany
S Kohl
M Christ-Adler
B Wissinger

Abt Pathophysiologie des Sehens und Neuroophthalmologie, Universitäts-Augenklinik Tübingen, Schleichstrasse 12, D-72076 Tübingen, Germany
S Kohl
M Christ-Adler
E Apfelstedt-Sylla
A Eckstein*
E Zrenner
B Wissinger

Augenklinik und Poliklinik, Universitätsklinikum Benjamin Franklin, Freie Universität Berlin, Hindenburgdamm 30, D-12200 Berlin, Germany
U Kellner

Correspondence to:
Dr Wissinger.

*Present address:
Universitäts-Augenklinik
Essen, Hufelandstrasse 55,
45122 Essen, Germany.

Received 7 November 1996
Revised version accepted for
publication 14 March 1997

of disease expression or phenotypes similar to those with reported RDS/peripherin mutations. Patients with the diffuse type of retinitis pigmentosa were excluded. Altogether 76 independent families comprising 138 available patients were subjected to molecular genetic analysis. Diagnoses in index patients included cone dystrophy (19 cases), cone-rod dystrophy (10 cases), macular dystrophy (18 cases), central areolar choroidal dystrophy (nine cases), pattern dystrophy (five cases), rod-cone dystrophy/RP (five cases), and some unclassified tapetoretinal dystrophies (10 cases). Autosomal dominant inheritance was delineated in 29 pedigrees.

DNA ISOLATION AND MUTATION ANALYSIS

DNA was isolated from peripheral venous blood samples using the procedure of Miller *et al.*¹⁷ Coding and flanking intronic/untranslated regions were amplified from total genomic DNA by means of the polymerase chain reaction. Exon 1 was amplified as two overlapping fragments with primer pairs a (5' AGCTGTGCTGTGGGAAGCAA)/a' (5' TTCCATCTGGCATACTTGGC) and b (5' TGCTATCCTGTGTCTTCAAC)/b' (5' TCTGACCCAGGACTGGAAG). Exons 2 and 3 were amplified as single fragments with primer pairs c (5' AAGCCCATCTCCAGCTGTCT)/c' (5' TTACCCTCTACCCCAGCTG) and d (5' AGATGGCCTCTAAATCTCCTCT)/d' (5' GGAGTGC ACTATTTCTCAGT), respectively. PCR amplified fragments of exons 1 and 2 were subjected to SSCP/heteroduplex analysis on non-denaturing acrylamide gels using a temperature controlled 20 cm vertical gel chamber. Two different electrophoresis conditions were used for each fragment. Conditions varied in gel strength (8%/10% acrylamide), presence/absence of glycerol (10% final concentration), and electrophoresis temperature (room temperature/4°C). Electrophoresis was performed with 6-10 W constant power overnight and gels were silver stained using the procedure of Bassam *et al.*¹⁸ Samples exhibiting mobility shifts in the SSCP/heteroduplex assay were subjected to DNA sequencing using the solid phase sequencing technology. For DNA sequencing exon 1 was amplified with primer pair FEO168 (5' GCCCTAAGTCTCCGCCTCT)/FEO 167 (5' CCAATATATTCATAGCTCTGACC, 5' biotinylated), exon 2 with primer pair c (see above)/FEO172 (5' CTACCCCCAGCTGCCAG, 5' biotinylated), and exon 3 with primer pair FEO174 (5' GGTCCAGCTCC-CAGCGATTCT)/FEO175 (5' GTAAGATG-GTGCCCTCCTTG, 5' biotinylated). PCR products were bound to Dynabeads™ (Dyna) and single stranded DNA was prepared according to protocols recommended by the manufacturer. Single strand DNA (either bound to Dynabeads or the complementary strand) was sequenced with the Single Strand Sequenase Dye Terminator Kit (Applied Biosystems) using primers a, a', b, b', c, c', d, and d', and analysed on an ABI 373A DNA sequencer. The coding portion of exon 3 of the RDS/peripherin gene was completely se-

quenced in at least one affected subject in the families under study. Cosegregation analysis within pedigrees was done either by SSCP/heteroduplex analysis, restriction digest analysis, or DNA sequencing as outlined above. In addition, a panel of control subjects was screened either by RFLP analysis with *AarII* (Gly208Asp, Ser289Leu) or by SSCP analysis (Trp246Arg).

Results

Analysis of exon 1 of the RDS/peripherin gene detected a variant SSCP pattern in pedigree W/K (figs 1 and 2) comprising eight affected family members. Sequence analysis showed a heterozygous C to T transition at nucleotide position (nt) 754¹⁰ resulting in an arginine to tryptophan substitution at codon 172 (CGG → TGG; Arg172Trp) of the RDS/peripherin gene. Segregation analysis via SSCP and direct DNA sequencing in four affected family members confirmed the coinheritance of the mutation with the disease phenotype in this family (data not shown). The mutation was absent in the spouse and one unaffected daughter of patient III.2. However, one apparently healthy male (IV.2), aged 32, was identified as a gene carrier.

Two other families with the Arg172Trp mutation have previously been described.^{14, 19} Thus, Arg172Trp is one of the few RDS/peripherin mutations which allow interfamilial phenotypic comparisons. Patients IV.4 and IV.5 in our family present a Stargardt-like clinical picture with symmetrical disciform areas of retinal pigment epithelial (RPE) atrophy and some interspersed patches of choroidal atrophy. However, the foveolar RPE is widely intact. These morphological changes correspond with central visual field defects but only mild foveolar sensitivity losses and normal peripheral fields. Visual acuity is normal or slightly reduced. Electroretinography (ERG) shows normal rod and cone signals. Their affected father (III.3) has disciform lesions at the posterior poles consistent with a central areolar choroidal atrophy, central visual field scotomas, and marked loss of visual acuity, but normal ERG recordings. The disease course and the morphological and psychophysical findings in our family closely resemble those reported in two other families with the Arg172Trp mutation,¹⁹ despite the fact that affected persons in these families had abnormal rod and cone ERG signals in later stages of the disease, indicating a more widespread retinal function loss.

In exon 2, five cases with aberrant migration patterns in the SSCP/heteroduplex analysis were observed. Solid phase DNA sequencing of the respective PCR products showed distinct nucleotide sequence alterations in each case, none of which has been reported previously. A heterozygous A to G transition at nt 829 resulting in a lysine to glutamic acid exchange at codon 197 (AAG → GAG; Lys197Glu) was observed in pedigree Ja (fig 1). Complete cosegregation between the Lys197Glu mutation and the disease was shown by SSCP analysis for four affected and seven unaffected

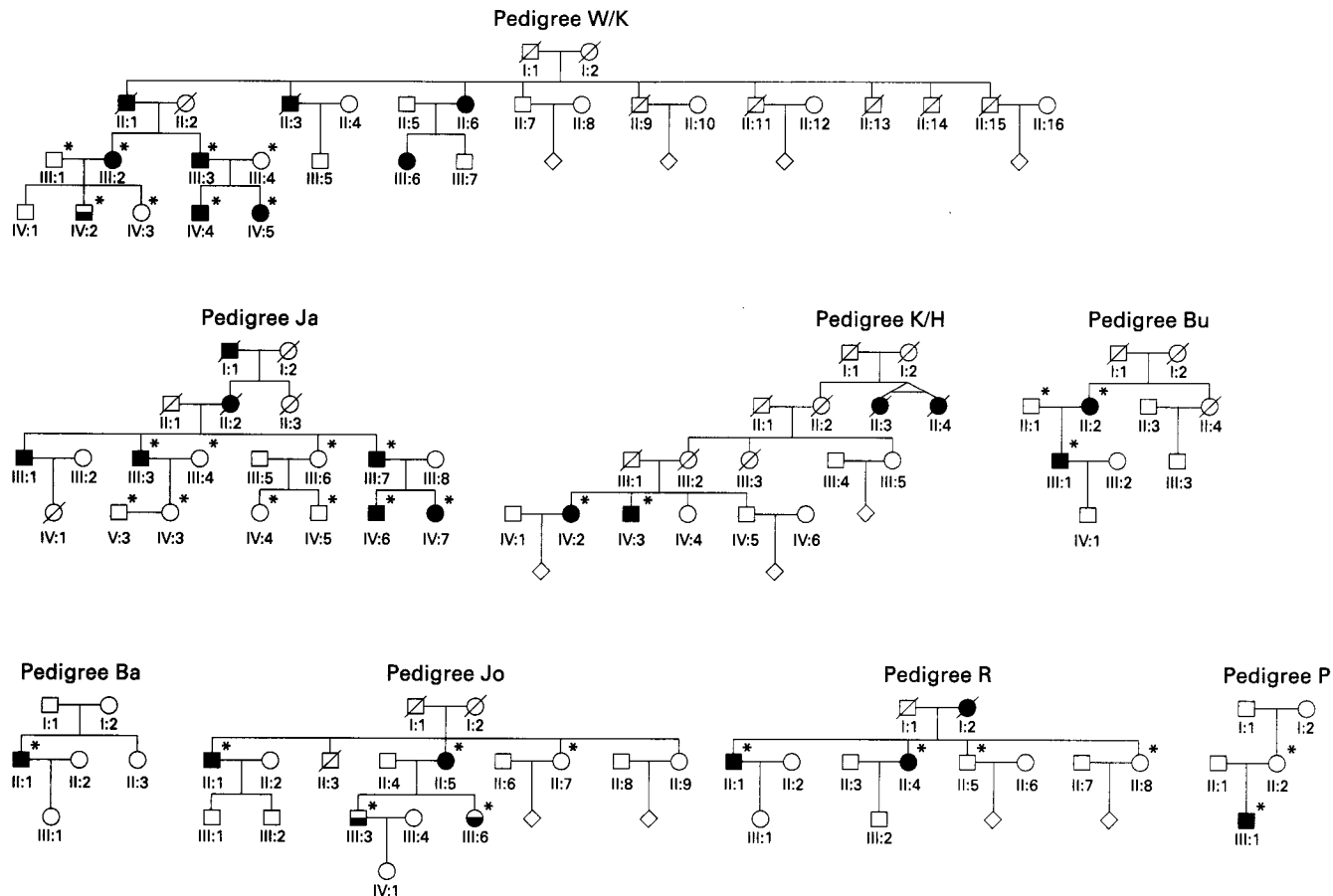


Figure 1 Pedigrees with a mutation in the *RDS/peripherin* gene. Black symbols indicate family members diagnosed with retinal degeneration or reported to be affected and white symbols those with no subjective visual complaints. Half blackened symbols denote gene carriers without subjective symptoms or questionable clinical status in pedigrees W/K and Jo. Subjects for whom samples were available for molecular analysis are indicated by asterisks.

family members (fig 3). Patients in family Ja suffer from a severe progressive retinal disease with macular dystrophy and widespread functional impairment affecting cone and rod photoreceptors. The diagnosis of cone-rod dystrophy was made.

Both affected sibs investigated in pedigree K/H (fig 1) carry a heterozygous single guanine base insertion at nt 862 or 863 of the *RDS/peripherin* gene sequence (Gly208insG, fig 2). This frameshift mutation results in a premature translational stop signal eight codons downstream of the insertion. Clinical examination of the patients showed foveal lesions accompanied by small central scotomas and mildly reduced rod and cone ERG amplitudes. Clinical findings were consistent with a pattern type foveal dystrophy. Autosomal dominant inheritance may be suspected although there was no history of visual complaints in the patients' maternal grandparents (fig 1).

A faint shift in the SSCP pattern was observed in patient III.1 in pedigree Bu (fig 1) who carries a heterozygous G to A transition at nt 863. This results in the replacement of glycine by an aspartate residue at codon 208 (GGC→GAC; Gly208Asp). The mutation introduces a new *Aat*II site which was used to show that the affected mother (II.2) also carries the disease allele (data not shown). There were no medical records available for the maternal grandparents who had died. On oph-

thalmological examination of patient III.1, central areolar pigment epithelial dystrophy of the retina was diagnosed in both eyes. The Gly208Asp mutation was absent in 75 independent controls.

DNA analysis of exon 2 showed a heteroduplex band but no aberrant SSCP pattern for the single patient in pedigree Ba (fig 2). He harbours a heterozygous C to T mutation at nt 955 which introduces a TAG stop codon for a glutamine residue at codon 239 (CAG→TAG; Gln239ter). A macular pattern dystrophy was diagnosed with fundus changes similar to patients carrying the Gly167Asp and Tyr258ter mutations.^{14,20} No other family member was available for molecular analysis or ophthalmological examination. It was reported that the patient's sister and daughter do not have any visual problems besides myopia.

Both affected sibs, II.1 and II.5, in family Jo (fig 1) were found to carry a heterozygous T to C change at nt 976 resulting in a replacement of tryptophan by arginine at codon 246 (TGG→CGG; Trp246Arg). However, the clinical picture of these patients is very inconsistent. The brother (II.1) has mild retinitis pigmentosa with visual field constrictions and a history of night blindness, whereas his older sister (II.5) suffers from adult onset vitelliform macular dystrophy with reduced visual acuity and central visual field loss complicated by the development of a subretinal neovascular membrane in one eye. The muta-

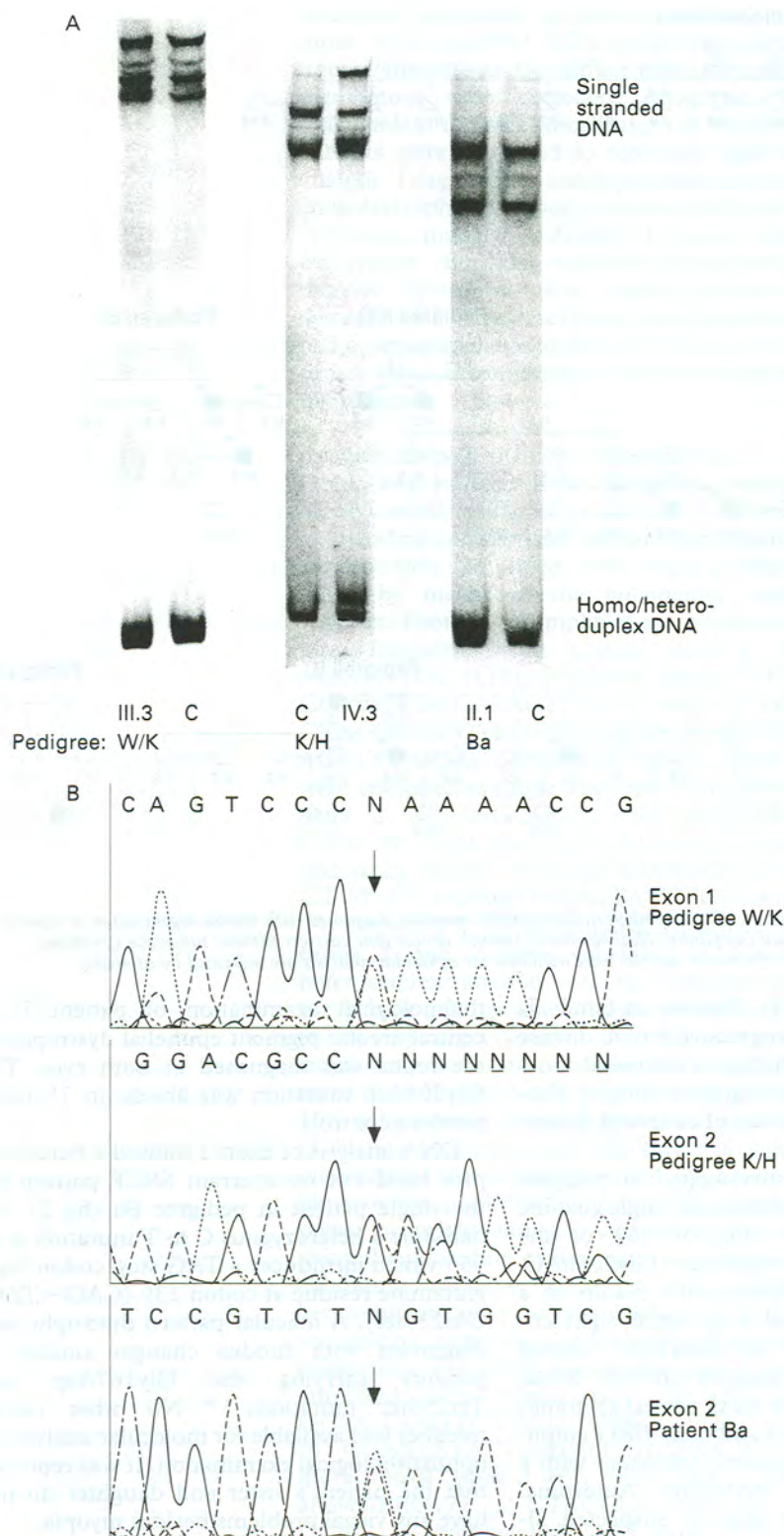


Figure 2 Detection of RDS/peripherin gene mutations by SSCP/heteroduplex and sequence analysis. (A) SSCP/heteroduplex patterns of selected mutations with single strand bands at the top and homo-/heteroduplex bands at the bottom. Left: analysis of exon 1 in patient III.3 of pedigree W/K. Middle: analysis of exon 2 in patient IV.3 of pedigree K/H. Right: analysis of exon 2 in patient II.1 of pedigree Ba. Lanes marked by C represent patterns obtained from control samples. (B) Representative electrophoretograms from direct PCR product sequencing. Sequencing was done for the opposite strand. Arrows indicate the heterozygous Arg172Trp mutation in pedigree W/K (top), the heterozygous single base insertion (Gly208 ins G) found in pedigree K/H (middle), and the heterozygous Glu239ter mutation in pedigree Ba (bottom).

tion was absent in the unaffected sib, II.7. However, we found that both children of patient II.5 also carry the Trp246Arg mutation. Neither the 17 year old nor the 19 year old report any noticeable visual complaints. Oph-

thalmological examination including funduscopy, static perimetry, colour vision testing, electroretinography, and electro-oculography showed only slight pigment epithelial changes and borderline ERG values. There is no information on affected family members in previous generations. However, they may not have been noticed without detailed ophthalmological examination because of the late onset of the disease and mild phenotypic expression. None of the 75 independent controls tested carried the Trp246Arg mutation.

Several known polymorphic sequence alterations in exon 3 hamper indirect SSCP/heteroduplex analysis. Therefore, we performed a complete sequence analysis of exon 3 in all 76 families under study. Among them we found two cases with previously unknown mutations in the coding sequence of the RDS/peripherin gene. Patient III.1 in pedigree R (fig 1) harbours a C to A transversion at nt 1095 which leads to a premature translational stop signal at codon 285 (TAC→TAA; Tyr285ter). Ophthalmological examination showed reduced visual acuity in conjunction with a retinal pattern dystrophy. Similar subjective visual complaints were reported for the dead mother. The mutation was also present in the patient's sister who suffers from a macular dystrophy, but absent in the two remaining healthy sibs.

Sequence analysis of exon 3 in the patient (III.1) in pedigree P (fig 1) showed a C to T substitution at nt 1106 resulting in a serine to leucine exchange at codon 289 (TCG→TTG; Ser289Leu). The patient was diagnosed as suffering from a progressive cone dystrophy with central pigment epithelium defects. However, the mutation was not detected in the patient's mother, who was found to suffer from an age related macular dystrophy. Thus, the Ser289Leu mutation found in patient III.1 must result from a de novo event or be inherited from the father for whom no medical history was available. Although this amino acid position is not strictly conserved between species, exclusion of the Ser289Leu mutation from a panel of 55 independent controls supports its association with the observed clinical phenotype.

Table 1 summarises the mutations found in this study in conjunction with the clinical phenotypes observed on ophthalmological examination.

Discussion

We have analysed patients from 76 independent pedigrees with various types of mostly central retinal degenerations for mutations in the RDS/peripherin gene. Since combined simultaneous SSCP and heteroduplex analysis was performed under two different gel conditions, and complete sequencing of exon 3 was done for all cases, we assume that mutation detection was achieved with high sensitivity in this study. Indeed, the Gln239ter would have been overlooked from the SSCP pattern alone, but was clearly detectable owing to the formation of a heteroduplex/homoduplex double band (fig 2).

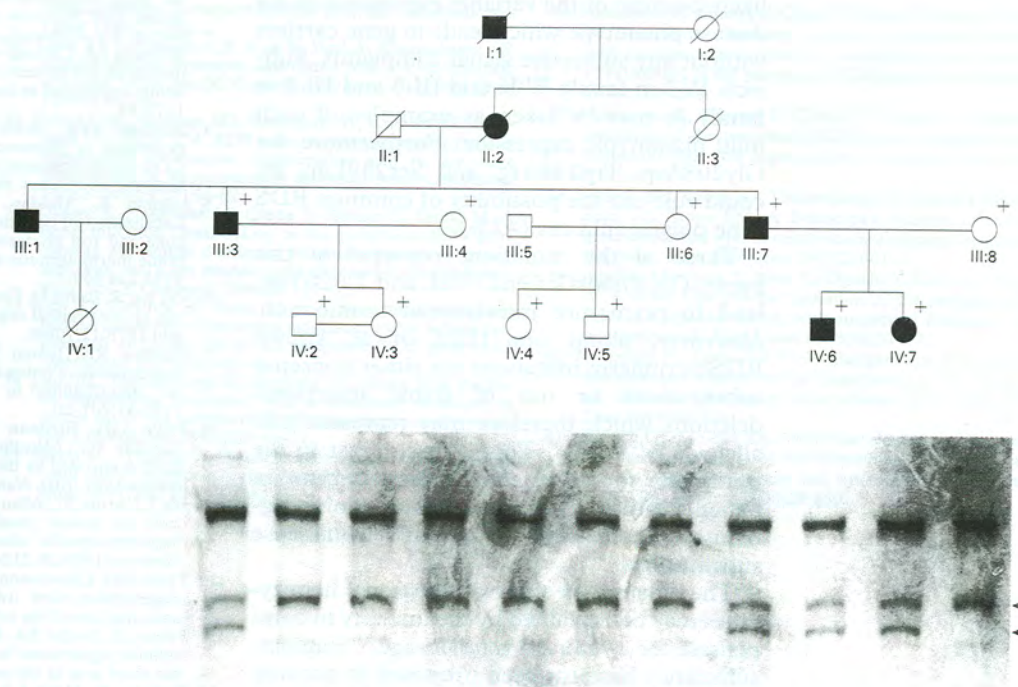


Figure 3 Cosegregation analysis of the Lys197Glu mutation in pedigree Ja by SSCP. Family members included in the analysis are indicated by crosses. Individual SSCP patterns are arranged according to the pedigree drawing above. Aberrant SSCP bands are indicated by arrows.

Altogether eight different mutations were found, each occurring in a single family. Thus, mutation screening was positive in 10.6% of all pedigrees, a very high rate for candidate gene analysis in human retinal dystrophies.²¹ This indicates that mutations in the RDS/peripherin gene are frequent causes of central retinal dystrophies.

A survey of published reports^{12-16, 20, 22-39} and databases (OMIM, The Human Gene Mutation Database) for mutations in the RDS/peripherin gene counted about three dozen different mutations reported so far. Seven of the eight mutations described in this paper (Lys197Glu, Gly208insG, Gly208Asp, Gln239ter, Trp246Arg, Tyr285ter, Ser289Leu) have not been reported previously and thus considerably increase the number of known RDS/peripherin mutations in human retinal diseases. Like the cases reported here the vast majority of known RDS/peripherin mutations are restricted to single pedigrees. These observations reflect the fact that there is a broad allelic spectrum of RDS/peripherin gene mutations, a situation similar to the rhodopsin gene mutations in autosomal dominant retinitis pigmentosa.⁴⁰ Although our patients are almost exclusively of central European descent, we did not observe any common disease alleles which

would be an indication of mutation hotspots or founder chromosomes.

Except for some clustering at codons 172/173 and codons 208 to 216, RDS/peripherin mutations are spread along the entire coding sequence including all exons. However, more than half of all known mutations are located in the D2 loop segment of the RDS/peripherin polypeptide, which forms an intradiscal extrusion as proposed by the secondary structure model.¹⁻⁴¹ It has been suggested that the D2 loop is involved in the formation of RDS homo-oligomers or hetero-oligomers with ROM1. These higher order structures may be necessary for disc membrane packaging and stabilisation.¹ The vast majority of known missense mutations in the RDS/peripherin gene are located within the D2 loop. The fact that the D2 loop segment is nearly completely conserved among all known RDS/peripherin sequences supports the notion that missense mutations in the D2 loop have deleterious effects. These mutations may disturb the formation and stability of protein aggregates in the disc membranes.

In our study all patients carried a single heterozygous mutation in the RDS/peripherin gene, which is suggestive of a dominantly inherited trait. With the exception of a few cases where digenic inheritance of mutations in the RDS/peripherin and the ROM1 genes has been assumed, autosomal dominant inheritance has been proposed in pedigrees with mutations in the RDS/peripherin gene.¹²⁻¹⁴ This mode of inheritance could be confirmed by family history and segregation analysis in at least two of our pedigrees (families W/K and Ja, figs 1 and 3). In the other pedigrees, autosomal inheritance could not always be definitely established from the family history. This may be the result of a new mutation event or more

Table 1 Observed RDS/peripherin gene mutations and their corresponding phenotypes

Mutations	Pedigree	Phenotype(s)
Arg172Trp	W/K	Stargardt's disease (IV.4, IV.5)/ central areolar choroidal dystrophy (III.3)
Lys197Glu	Ja	Cone-rod dystrophy
Gly208 ins G	K/H	Pattern dystrophy
Gly208Asp	Bu	Central areolar pigment epithelial dystrophy
Gln239ter	Ba	Pattern dystrophy
Trp246Arg	Jo	Retinitis pigmentosa (II.1)/ adult onset vitelliform macular dystrophy (II.5)
Tyr285ter	R	Pattern dystrophy
Ser289Leu	P	Cone dystrophy

Specific patients are shown in brackets.

likely because of the variable expression of the disease phenotype which leads to gene carriers without any subjective visual complaints. Subjects IV.2 in family W/K and III.3 and III.5 in family Jo may be taken as examples of such mild phenotypic expression. Furthermore, for Gly208Asp, Trp246Arg, and Ser289Leu, we could rule out the possibility of common RDS gene polymorphisms (>1%).

Three of the mutations reported in this paper, Gly208insG, Gln239ter, and Tyr285ter, lead to premature translational termination. Moreover, about one third of all known RDS/peripherin mutations are either nonsense substitutions or out of frame insertions/deletions which therefore may represent null alleles.^{14 22 27-30 33-35 38} This is in contrast to the mutations found in the rhodopsin gene in patients with autosomal dominant retinitis pigmentosa which are almost exclusively missense substitutions.⁴⁰

The deleterious effect of functional hemizygotes may be explained by the inability to compensate for a reduced gene dosage.²⁹ Haploinsufficiency has also been proposed to account for the semidominant acting molecular defect in the *rds* mouse where a 9.2 kb insertion into exon 2 disrupts the RDS/peripherin reading frame.⁹

However, it is obvious that a simple gene dosage model cannot explain the highly variable phenotypes associated with potential null alleles of the RDS/peripherin gene. Intrafamilial variability in clinical expression suggests that other genetic or environmental factors may determine the actual type and course of the disease in a person. It has been shown that in some families with digenic inherited retinitis pigmentosa only simultaneous mutations in the RDS/peripherin and the ROM1 gene are sufficient to cause retinal degeneration.¹⁶ Consequently, it may be reasoned that in cases where a RDS/peripherin mutation alone is sufficient to account for a clinical phenotype, the actual sequence and allelic composition of ROM1 and of other as yet unidentified structural elements may moderate the disease expression.

Taken together, the observations from mutation analysis argue for two different pathogenic mechanisms of RDS/peripherin mutations: missense mutations in the D2 loop may interfere with the formation of functional higher order homo- or hetero-oligomeric protein structures, whereas a gene dosage effect may act in the case of probable null alleles. Gene and protein expression analysis in patients or in appropriate in vitro systems will be necessary to elucidate further the molecular pathogenicity of RDS/peripherin gene mutations.

We would like to thank Drs Klaus Rütger, Ulf Kretschmann, and Stefan Kremmer for ophthalmological examination of some of the patients. This work was supported by grants from the Deutsche Forschungsgemeinschaft (Wi1189/1-2, Ru457/1-3, Ke442/7-1, and Zr1/7-3).

- 1 Travis GH, Sutcliffe JG, Bok D. The retinal degeneration slow (*rds*) gene product is a photoreceptor disc membrane-associated glycoprotein. *Neuron* 1991;6:61-70.
- 2 Connell G, Bascom R, Molday L, Reid D, McInnes R, Molday RS. Photoreceptor peripherin is the normal product of

- the gene responsible for retinal degeneration in the *rds* mouse. *Proc Natl Acad Sci USA* 1991;88:723-6.
- 3 Bascom RA, Manara S, Collins L, Molday RS, Kalnins VI, McInnes RR. Cloning of the cDNA for a novel photoreceptor membrane protein (*rom-1*) identifies a disk rim protein family implicated in human retinopathies. *Neuron* 1992;8:1172-84.
- 4 Goldberg AFX, Moritz OL, Molday RS. Heterologous expression of photoreceptor peripherin/*rds* and *rom-1* in COS-1 cells: assembly, interaction and localization of multisubunit complexes. *Biochemistry* 1995;34:14213-19.
- 5 Arikawa K, Molday LL, Molday RS, Williams DS. Localization of peripherin/RDS in the disk membranes of cone and rod photoreceptors: relationship to disk membrane morphogenesis and retinal degeneration. *J Cell Biol* 1992;116:659-67.
- 6 Van Nie R, Ivanyi D, Demant P. A new H-2 linked mutation, *rds*, causing retinal degeneration in the mouse. *Tissue Antigens* 1978;12:106-8.
- 7 Hawkins RK, Jansen HG, Sanyal S. Development and degeneration of retina in the *rds* mutant mice: photoreceptor abnormalities in the heterozygotes. *Exp Eye Res* 1985;41:701-20.
- 8 Travis GH, Brennan MB, Danielson PE, Kozak CA, Sutcliffe JG. Identification of a photoreceptor-specific mRNA encoded by the gene responsible for retinal degeneration slow (*rds*). *Nature* 1989;338:70-3.
- 9 Ma J, Norton JC, Allen AC, et al. Retinal degeneration slow (*rds*) in mouse results from simple insertion of a t haplotype-specific element into protein-coding exon II. *Genomics* 1995;28:212-19.
- 10 Travis GH, Christerson L, Klisak I, et al. The human retinal degeneration slow (*rds*) gene: chromosomal assignment and structure of the mRNA. *Genomics* 1991;10:733-9.
- 11 Farrar GJ, Jordan SA, Kenna P, et al. Autosomal dominant retinitis pigmentosa: localization of a disease gene (RP6) to the short arm of chromosome 6. *Genomics* 1991;11:870-4.
- 12 Kajiwara K, Hahn LB, Mukai S, Travis GH, Berson EL, Dryja TP. Mutations in the human retinal degeneration slow gene in autosomal dominant retinitis pigmentosa. *Nature* 1991;354:480-3.
- 13 Farrar GJ, Kenna P, Jordan SA, et al. A three-base-pair deletion in the peripherin-RDS gene in one form of retinitis pigmentosa. *Nature* 1991;354:478-90.
- 14 Wells J, Wroblewski J, Keen J, et al. Mutations in the human retinal degeneration slow (RDS) gene can cause either retinitis pigmentosa or macular dystrophy. *Nat Genet* 1993;3:213-17.
- 15 Weleber RG, Carr RE, Murphy WH, Sheffield VC, Stone EM. Phenotypic variation including retinitis pigmentosa, pattern dystrophy, and fundus flavimaculatus in a single family with a deletion of codon 153 or 154 of the peripherin/RDS gene. *Arch Ophthalmol* 1993;111:1531-42.
- 16 Kajiwara K, Berson EL, Dryja TP. Digenic retinitis pigmentosa due to mutations at the unlinked peripherin/RDS and ROM1 loci. *Science* 1994;264:1604-8.
- 17 Miller SA, Dykes DD, Polesky HF. A simple salting out procedure for extracting DNA from human nucleated cells. *Nucleic Acids Res* 1988;16:1215.
- 18 Bassam BJ, Caetano-Anolles G, Gresshoff PM. Fast and sensitive silver staining of DNA in polyacrylamide gels. *Anal Biochem* 1991;196:80-3.
- 19 Wroblewski J, Wells J, Eckstein A, et al. Macular dystrophy associated with mutations at codon 172 in the human retinal degeneration slow gene. *Ophthalmology* 1994;101:12-22.
- 20 Nichols BE, Sheffield VC, Vandenburg K, Drack AV, Kimura AE, Stone EM. Butterfly-shaped pigment dystrophy of the fovea caused by a point mutation in codon 167 of the RDS gene. *Nat Genet* 1993;3:202-7.
- 21 Dryja TP, Li T. Molecular genetics of retinitis pigmentosa. *Hum Mol Genet* 1995;4:1739-43.
- 22 Apfelstedt-Sylla E, Theischen M, Rütger K, Wedemann H, Gal A, Zrenner E. Extensive intrafamilial phenotypic variation among patients with autosomal dominant retinal dystrophy and mutations in the human RDS/peripherin gene. *Br J Ophthalmol* 1995;79:28-34.
- 23 Farrar GJ, Kenna P, Jordan SA, et al. Autosomal dominant retinitis pigmentosa: a novel mutation at the peripherin/RDS locus in the original 6p-linked pedigree. *Genomics* 1992;14:805-7.
- 24 Feist RM, White MF, Skalka H, Stone EM. Choroidal neovascularization in a patient with adult foveolar dystrophy and a mutation in the retinal degeneration slow gene (Pro 210 Arg). *Am J Ophthalmol* 1994;118:259-60.
- 25 Fishman GA, Stone E, Gilbert LD, Vandenburg K, Sheffield VC, Heckenlively JR. Clinical features of a previously undescribed codon 216 (proline to serine) mutation in the peripherin/retinal degeneration slow gene in autosomal dominant retinitis pigmentosa. *Ophthalmology* 1994;101:1409-21.
- 26 Gorin M, Jackson KE, Ferrell RE, et al. A peripherin/retinal degeneration slow mutation (Pro-210-Arg) associated with macular and peripheral retinal degeneration. *Ophthalmology* 1995;102:245-55.
- 27 Grüning G, Millan JM, Meins M, et al. Mutations in the human peripherin/RDS gene associated with autosomal dominant retinitis pigmentosa. *Hum Mutat* 1994;3:321-3.
- 28 Jacobsen SG, Cideciyan AV, Kemp CM, Sheffield VC, Stone EM. Photoreceptor function in heterozygotes with insertion or deletion mutations in the RDS gene. *Invest Ophthalmol Vis Sci* 1996;37:1662-74.
- 29 Kajiwara K, Sandberg MA, Berson EL, Dryja TP. A null mutation in the human peripherin/RDS gene in a family

- with autosomal dominant retinitis punctata albescens. *Nat Genet* 1993;3:208-12.
- 30 Keen TJ, Inglehearn CF, Kim R, Bird A, Bhattacharya SS. Retinal pattern dystrophy associated with a 4 bp insertion at codon 140 in the RDS-peripherin gene. *Hum Mol Genet* 1994;3:367-8.
 - 31 Kemp CM, Jacobsen SG, Cideciyan AV, Kimura AE, Sheffield VC, Stone EM. RDS gene mutations causing retinitis pigmentosa or macular degeneration lead to the same abnormality in photoreceptor function. *Invest Ophthalmol Vis Sci* 1994;35:3154-62.
 - 32 Kikawa E, Nakazawa M, Chida Y, Shiono T, Tamai M. A novel mutation (Asn244Lys) in the peripherin/RDS gene causing autosomal dominant retinitis pigmentosa associated with bull's eye maculopathy detected by nonradioisotopic SSCP. *Genomics* 1994;20:137-9.
 - 33 Kim RY, Dollfus H, Keen TJ, et al. Autosomal dominant pattern dystrophy of the retina associated with a 4-base pair insertion at codon 140 in the peripherin/RDS gene. *Arch Ophthalmol* 1995;113:451-5.
 - 34 Lam BL, Vandenburgh K, Sheffield VC, Stone EM. Retinitis pigmentosa associated with a dominant mutation in codon 46 of the peripherin/RDS gene (arginine-46-stop). *Am J Ophthalmol* 1995;119:65-71.
 - 35 Meins M, Grüning G, Blankennagel A, et al. Heterozygous "null allele" mutation in the human peripherin/RDS gene. *Hum Mol Genet* 1993;2:2181-2.
 - 36 Nakazawa M, Kikawa E, Chida Y, Wada Y, Shiono T, Tamai M. Autosomal dominant cone-rod dystrophy associated with mutations in codon 244 (Asn244His) and codon 184 (Tyr184Ser) of the peripherin/RDS gene. *Arch Ophthalmol* 1996;114:72-8.
 - 37 Nakazawa M, Kikawa E, Chida Y, Tamai M. Asn244His mutation of the peripherin/RDS gene causing autosomal dominant cone-rod degeneration. *Hum Mol Genet* 1994;3:1195-6.
 - 38 Nichols BE, Drack AV, Vandenburgh K, Kimura AE, Sheffield VC, Stone EM. A 2-base pair deletion in the RDS gene associated with butterfly-shaped pigment dystrophy of the fovea. *Hum Mol Genet* 1993;2:601-3.
 - 39 Saga M, Mashima Y, Akeo K, Oguchi Y, Kudoh J, Shimizu N. A novel Cys-214-Ser mutation in the peripherin/RDS gene in a Japanese family with autosomal dominant retinitis pigmentosa. *Hum Genet* 1993;92:519-21.
 - 40 Rosenfeld PJ, Dryja TP. Molecular genetics of retinitis pigmentosa and related retinal degenerations. In: Wiggs JL, ed. *Molecular genetics of ocular disease*. New York: Wiley-Liss, 1996:99-126.
 - 41 Connell GJ, Molday RS. Molecular cloning, primary structure and orientation of the vertebrate photoreceptor cell protein peripherin in the rod outer segment disk membrane. *Biochemistry* 1990;29:4691-8.