

Cone dystrophies with negative photopic electroretinogram

Ulrich Kellner, Michael H Foerster

Abstract

A scotopic electroretinogram with an a-wave amplitude larger than the b-wave amplitude traditionally is termed 'negative'. Six male patients with negative photopic electroretinograms were examined; three of them suffered from progressive cone dystrophy, in which negative electroretinograms are unusual. Another patient without symptoms was the brother of a patient with cone dystrophy. These patients are compared with others who characteristically have negative electroretinograms - one patient with incomplete congenital stationary night blindness and another with X linked congenital retinoschisis. Differential diagnosis between these unusual cases of cone dystrophies and X linked retinoschisis or congenital stationary night blindness was possible with funduscopy, adaptometry, and evaluation of progression, but not with the electroretinogram. Inner retinal defects may occur in cone dystrophies as indicated by the negative electroretinogram. The waveform variations between our patients may be due to different inner retinal defects. The findings in two brothers indicate that cone dystrophy and inner retinal defects may be inherited separately.

(*Br J Ophthalmol* 1993; 77: 404-409)

Freie Universität Berlin,
Klinikum Steglitz,
Augenlinik und
Poliklinik, Berlin,
Germany
U Kellner
M H Foerster

Correspondence to:
Dr Ulrich Kellner, FU Berlin,
Klinikum Steglitz,
Augenlinik und Poliklinik,
Hindenburgdamm 30, D/W
1000 Berlin 45, Germany.

Accepted for publication
13 November 1992

Cone dystrophies are a group of diseases involving the function of retinal cones in various ways.^{1,2} Several different primary defects within the retina seem to exist: degenerations can be separated according to the retinal area and cone types affected. Different involvement of central

and peripheral cones has been described.^{3,4} Recently selective cone dystrophies affecting only one or two cone types have been separated from generalised cone dystrophies.⁵⁻⁷ In inherited retinal degenerations, however, the location of the primary retinal defect has always been attributed to the photoreceptor-retinal pigment epithelium complex.³

Occasionally electroretinographic findings were described, that indicated a dysfunction of inner retinal layers in cone dystrophies,⁸⁻¹⁰ yet, these findings were ignored. In those cases the b-wave was severely reduced compared with a normal or moderately reduced a-wave, resulting in a 'negative' photopic electroretinogram.¹¹ Similar electroretinograms were seen in incomplete congenital stationary night blindness,¹²⁻¹⁶ and X linked congenital retinoschisis.^{17,18}

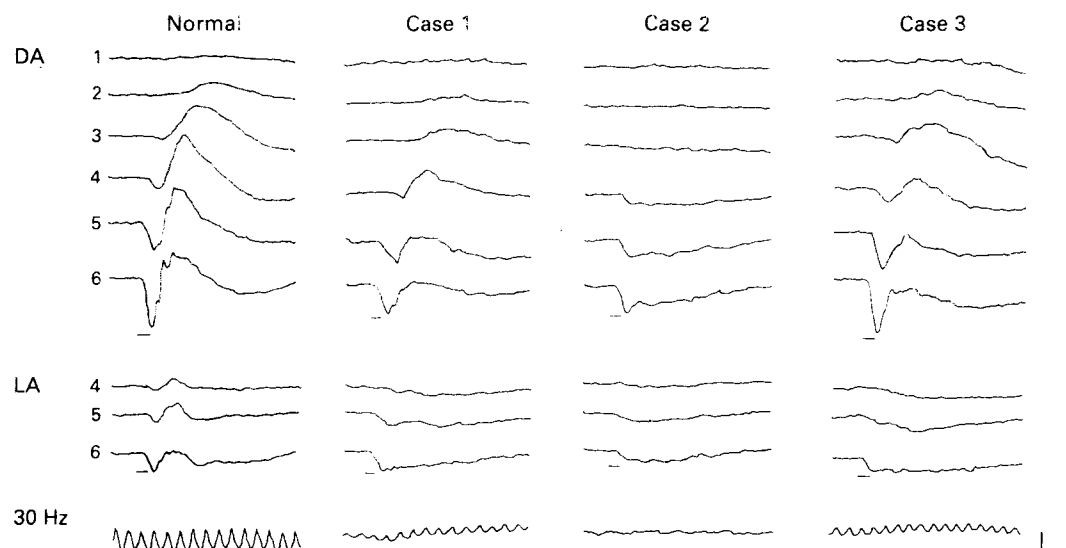
We analysed retrospectively the records of three patients who suffered from cone dystrophies, had a negative photopic electroretinogram, and in whom X linked retinoschisis and congenital stationary night blindness could be excluded. The patients are compared with patients with incomplete congenital stationary night blindness and X linked retinoschisis.

Electrophysiological methods

The electro-oculographic technique was as described by Rhode *et al.*¹⁹ The normal range of the light peak/baseline ratio was 187 (SD 36)% (± 2 SD); therefore the lower limit of the normal range was 151%.

The electroretinographic recording method has been described in detail.^{18,20} The recording protocol includes all stimuli specified by the

Figure 1
Electroretinographic recordings from a normal person and cases 1-3 (progressive cone dystrophies). In the upper rows the responses to increasing stimulus intensities when dark adapted (DA) are shown. In the middle the responses at light adaptation (LA) and below the 30 Hz flicker response. The lines below the recordings indicate stimulus duration and numbers in front of the recordings stimulus intensities. Vertical calibration mark indicates 100 μ V. Horizontal calibration mark indicates 20 ms for single-flash recordings and 50 ms for flicker stimulation.



standard for clinical electroretinography.²¹ Stimulus duration was 10 ms. Six different light intensities (1–6) increasing in steps of one logarithmic unit from the b-wave threshold of the normal eye were used for the dark adapted recordings. The maximum light intensity was 7.8 cd·s/m². The light adapted recordings were performed under white light adaptation to a background of 4.5 cd·m⁻² and with the light stimuli 4–6. The 30 Hz flicker stimulus had the light intensity 5. White light from a xenon light source served as stimulus in all examinations. The light source was filtered for infrared with Schott filter KG2IR. A normal electroretinogram is shown in Figure 1. The normal ranges consist of the mean value (± 2 SD) from 40 volunteers.

Clinical findings

The clinical and electrophysiological findings of our patients are summarised in Table 1. The general and medical history was unremarkable in all patients. Acquired retinal degenerations owing to drug toxicity or infectious diseases like chorioretinitis or uveitis could be excluded.

CASE 1 (PROGRESSIVE CONE DYSTROPHY)

The 61-year-old patient suffered from progressive visual loss for more than 10 years. His visual acuity was 0.4 in both eyes. Pigment irregularities were seen in the macular area; the peripheral retina was normal. Visual field testing revealed paracentral scotomas in both eyes. He was unable to identify the Ishihara plates and the Panel D15 desaturé test. Testing with the Nagel

anomaloscope revealed a deuteranomalous loss with a broad range of matches for the right (20–73/13) and left eye (30–67/13). The light rise of the electro-oculogram was reduced.

CASE 2 (PROGRESSIVE CONE-ROD DYSTROPHY)

The patient was first examined because of a corneal injury on the left eye at the age of 35 years. He had no visual problems at that time. Visual acuity was 1.0 on the right eye and 0.6 on the left owing to a corneal epithelial erosion. The fundusoscopic appearance was described as normal. Eight years later the patient was seen with a 5 year history of progressive visual loss. His visual acuity was reduced to 0.3 in both eyes. The intraocular pressure was normal as it was at the first examination. Fundus examination revealed paleness of the optic disc and a narrowing of the vessels. The visual fields showed a slight concentric narrowing in both eyes. Colour vision was severely disturbed. Ishihara plates could not be read. Panel D15 and Farnsworth-Munsell 100 hue tests showed several errors without a typical axis. With the Nagel anomaloscope he found matches in accordance with achromatopsia. Dark adaptation, tested with the Goldmann-Weekers adaptometer, was reduced by 1.5 logarithmic units. The light rise of the electro-oculogram was reduced. The progressive visual loss excludes the diagnosis of congenital stationary night blindness in this patient.

CASE 3 (PROGRESSIVE CONE DYSTROPHY)

A short overview of the clinical findings and the results of colour electroretinography of this

Table 1 Clinical and electrophysiological findings in patients with negative photopic electroretinogram

No	Age	Sex	Prog	Eye	VA	Refra	Fund	Colour	VF	DA	EOG	ERG			Dx
												d-b/a	l-b/a	30 Hz	
1	61	m	++	R	0.4	+3.0	PI	deut	cent		144	bord	red	40	cd
				L	0.4	+3.25			144						
2	43	m	+++	R	0.3	-1.25	PC	achr	conc	3.0	131	red	PIII	0	crd
				L	0.3	-1.25			128						
3	40	m	+	R	0.4	+1.25	PI	achr	cent	n	125	red	PIII	60	cd
				L	0.3	+1.25			128						
4	44	m	-	R	1.0	± 0	n	n	n	n	135	red	red	90	?
				L	0.04	+7.5			133						
5	33	m	-	R	0.4	-2.5	n	deut	n	2.9	150	red	red	20	csnb
				L	0.4	-3.25			146						
6	29	m	-	R	0.4	+2.0	R	dist	n		183	red	red	65	xlr
				L	0.2	+3.0			185						
G1	35	m	++	R	0.1	-4.0	BE	achr	cent		n	n	red	cd	
				L	0.1	-3.75									
G2	28	m	++	R	0.3	-1.5	n	dist	para		n	n	red	cd	
				L	0.25	-1.5									
G3	25	f	+	R	0.5	-0.5	BE	achr	para		red	n	red	cd	
				L	0.25	-0.5									
G4	28	m	++	R	0.25	-2.75	BE	achr	para		red	n	red	cd	
				L	0.1	-3.5									
G5	22	f	-	R	0.7	± 0	BE	dist	para		n	n	red	cd	
				L	0.7	± 0									
Y	44	f	-	R	0.8		PC	dist	peri	n		n	red	red	?
				L	0.8										
W1	35	m		R	0.7		BE	dist			n	n	red	red	cd
				L	0.7										
W2	18	m		R	0.2		BE	dist			n	n	red	red	cd
				L	0.06										
W3	38	m		R	0.02		PC	dist			red	n	red	red	cd
				L	0.02										

Visual acuity at the last follow-up examination, refraction, and the light rise of the electro-oculogram is given for both eyes separately. All other values were given once for a patient if there was no difference between both eyes. Empty fields indicate missing dates. Normal range: electro-oculography: 187 (SD 36)% (lower limit, 151%); 30 Hz flicker response: 136 (SD 52) μ V (lower limit 84 μ V). G1–5 = patients of Grey *et al*⁸; Y = patient of Young *et al*⁹; W1–3 = patients of Wakabayashi¹⁰. Prog = progression; VA = visual acuity; Refra = refraction; Fund = fundusoscopic findings; VF = visual fields; DA = dark adaptation; EOG = electro-oculogram; ERG = electroretinogram; 30 Hz = 30 Hz flicker amplitude; Dx = diagnosis; d = dark; l = light adapted; m = male; f = female; PI = pigment irregularities; PC = pigment clumping; n = normal; R = retinoschisis; BE = bull's eye; deut = deuteranopia; achr = achromatopsia; dist = disturbed without specific axis; conc = concentric narrowing; cent = central scotoma; para = paracentral scotoma; peri = peripheral scotoma; bord = borderline; red = reduced; PIII = PIII component; cd = cone dystrophy; crd = cone rod dystrophy; csnb = congenital stationary night blindness (incomplete type); xlr = X linked retinoschisis; ? = no clinical signs but altered electroretinogram.

patient have been described previously as cone dystrophy with missing b-waves at light adaptation.⁷ He has been observed for 22 years, beginning at the age of 18 years. He had complained of reduced visual acuity since childhood. The visual acuity was 0.5 in the right eye and 0.4 in the left at the first examination and 0.4 in the right and 0.3 in the left at the last follow up. Mild pigment irregularities in the macular area remained unchanged. Central scotomas were found in both eyes. Colour vision testing revealed a protanomaly at the first examination. At the age of 40 achromatopsia was found on the Nagel anomaloscope and the Farnsworth-Munsell 100 hue test. The dark adaptation had a normal final threshold. The electro-oculogram showed a reduced light rise. Although the visual acuity was relatively stable, the progressive colour vision deficiency indicates a slow progressive cone dystrophy in this patient.

CASE 4 (FAMILY MEMBER)

The brother of case 3 was examined at the age of 44 years. His visual acuity was 1.0 in the right eye and 0.04 in the left owing to anisometropia of +7.5 dioptres. The funduscopy appearance was normal as were the visual fields, colour vision, and dark adaptation. The light rise of the electro-oculogram was reduced.

CASE 5 (INCOMPLETE CONGENITAL STATIONARY NIGHT BLINDNESS)

The 33-year-old patient had a reduced visual acuity and difficulties with seeing at night without progression since childhood. He had a visual acuity of 0.4 in both eyes. The funduscopy appearance and the visual fields were normal. Deuteranopia was revealed by the Nagel anomaloscope. Dark adaptation measured with the Goldmann-Weekers adaptometer showed a reduced final threshold at 1.6 logarithmic units. The light rise of the electro-oculogram was reduced.

CASE 6 (X LINKED RETINOSCHISIS)

This 29-year-old man suffering from X linked

congenital retinoschisis is a representative example from a recently described series.¹⁸ His two brothers were also affected. His visual acuity was 0.4 on the right and 0.2 on the left eye. Both eyes showed a macular retinoschisis with normal periphery. The visual fields were normal. Colour vision was disturbed with misreading of four Ishihara plates and an extensive range of matches from 34/13 to 48/13 at the Nagel anomaloscope. The light rise of the electro-oculogram was normal in both eyes.

Electroretinographic findings

In Figures 1 and 2 the electroretinographic recordings are shown and in Figures 3-6 the amplitude-intensity functions of all patients are given. An overview of the electrophysiological findings including the 30 Hz flicker amplitudes is listed in Table 1 for comparison with the patients described in the literature.

CASE 1

In case 1 the a-wave amplitudes were borderline at lower stimulus intensities and subnormal at the higher stimulus intensities when dark adapted. The b-wave amplitudes were reduced at all stimulus intensities and therefore the b/a ratios were borderline. When light adapted, the a-wave amplitudes were normal, but the b-wave amplitudes and b/a ratios were severely reduced. The 30 Hz flicker amplitude was reduced. The a-wave latencies were normal, the b-wave implicit times were delayed at dark adaptation.

CASE 2

In case 2 the electroretinogram showed borderline a-wave amplitudes at lower stimulus intensities and subnormal amplitudes at higher intensities at dark and light adaptation. When dark adapted, small b-waves were found at higher stimulus intensities and accordingly the b/a ratios were severely reduced. The implicit times of these b-waves were 30-34 ms in both eyes without difference between the stimulus intensities 5 and 6. These implicit times were about 8 ms shorter than the implicit time of the

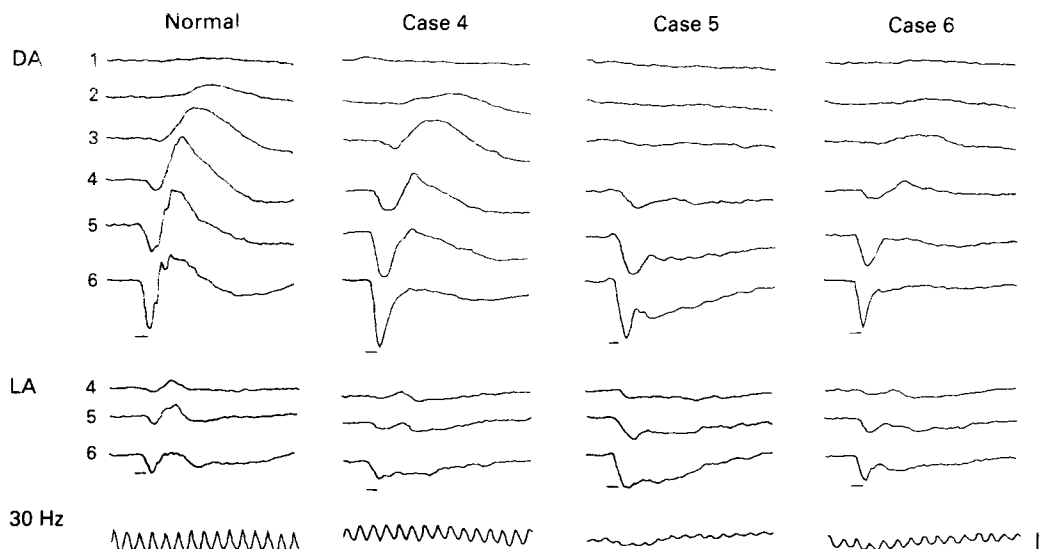
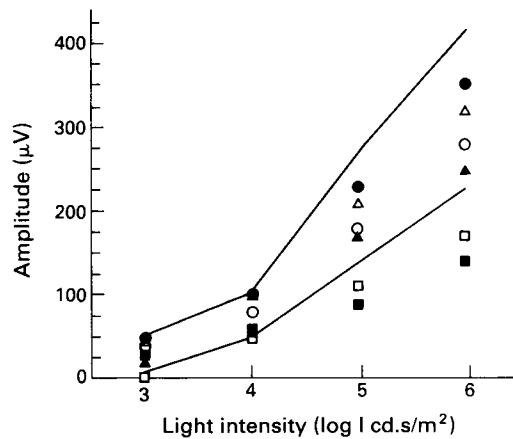


Figure 2
Electroretinographic recordings from a normal person and case 4 (family member), case 5 (congenital stationary night blindness, and case 6 (X linked retinoschisis). For detailed explanation see Figure 1.

Figure 3 Dark adapted a-wave amplitudes in patients with negative photopic electroretinograms. Three patients with progressive cone dystrophy and a family member: case 1 (□), case 2 (■), case 3 (○), and the brother of case 3 (case 4, ●). One patient with incomplete congenital stationary night blindness (case 5, △), and one patient with X-linked congenital retinoschisis (case 6, ▲). The normal range indicated by two lines is the mean value (± 2 SD). The stimulus intensity is indicated on the horizontal axis.



b-wave in normals, which is 42 (SD 1.8) ms at stimulus intensity 5, and 39 (SD 1.4) ms at stimulus intensity 6. At light adaptation a-waves and no measurable b-waves were present. The responses, therefore, looked like an isolated PIII-component, which corresponds to the photoreceptor response.²² There was no response to 30 Hz flicker stimulation.

CASE 3

In case 3 the a-wave amplitudes were normal when dark adapted and borderline when light adapted. The b-wave amplitudes were borderline at lower stimulus intensities and reduced at stimulus intensities 4–6 when dark adapted. The b/a ratios were reduced at all stimulus intensities when dark adapted. At light adaptation no b-waves were measurable. The latencies and implicit times of a- and b-waves, when present, were normal. The 30 Hz flicker response was reduced. The electroretinogram was unchanged within the last 3 years of follow up. Tested with colour stimuli in the electroretinogram and psychophysically, this patient had a severe red cone dysfunction and only a moderate green cone dysfunction.⁷

CASE 4

In case 4 the a-wave amplitudes were normal at all recording conditions. The b-wave amplitudes were normal at lower stimulus intensities when

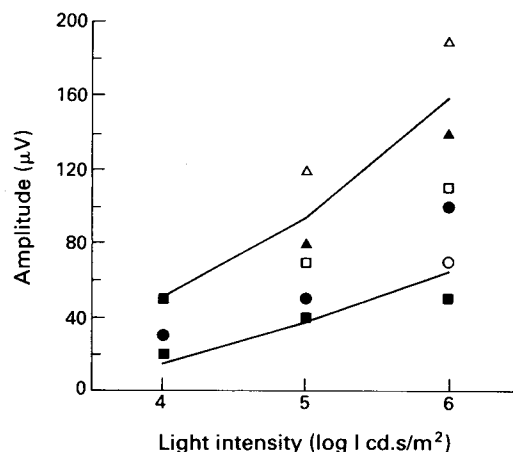


Figure 4 Light adapted a-wave amplitudes in patients with negative photopic electroretinograms. For further explanation see Figure 3.

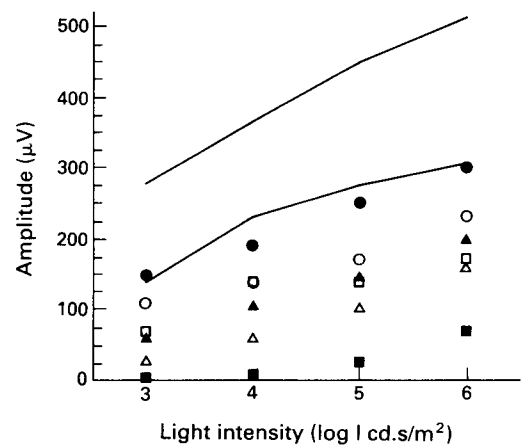


Figure 5 Dark adapted b-wave amplitudes in patients with negative photopic electroretinograms. For further explanation see Figure 3.

dark adapted. They were reduced just below the lower limit of the normal range at high stimulus intensities when dark adapted and under light adapted conditions. The b/a ratios were reduced when dark adapted. When light adapted, they were borderline at lower stimulus intensities and reduced at maximum stimulus intensity. The latencies and implicit times of a- and b-waves were normal. The 30 Hz flicker response was within the lower normal range.

CASE 5

Case 5 had normal a-wave amplitudes at dark adaptation and large amplitudes at light adaptation. The b-waves were reduced in all stimulus conditions and so were the b/a ratios. The b-wave implicit time was short (27 ms) at the highest stimulus intensity when dark adapted and was normal in all other recordings. The 30 Hz flicker response was severely reduced.

CASE 6

Case 6 showed normal a-waves in all recordings. The b-waves were reduced when dark adapted and normal when light adapted. The b/a ratios were reduced in all recordings. The latencies and implicit times of a- and b-waves were normal. The 30 Hz flicker response was reduced. It should be noted that in this and all other

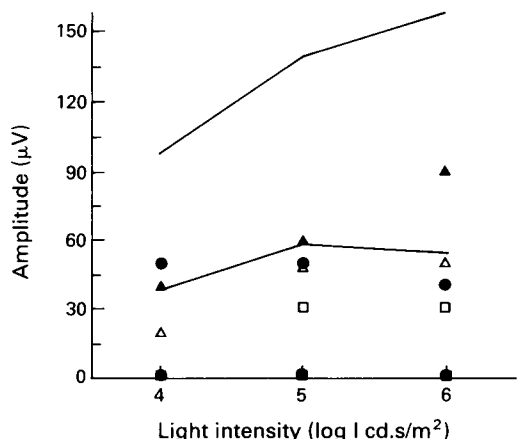


Figure 6 Light adapted b-wave amplitudes in patients with negative photopic electroretinograms. For further explanation see Figure 3.

previously examined patients with X linked retinoschisis¹⁸ a small b-wave was always present when light adapted.

Discussion

A 'negative' electroretinogram has been defined as a waveform in which the a-wave amplitude is larger than the b-wave amplitude, resulting in a b/a ratio below 1.0.¹¹ At dark adapted conditions, a negative electroretinogram is a typical finding in different forms of congenital stationary night blindness,¹²⁻¹⁶ X linked congenital retinoschisis,^{17,18} central retinal vein occlusion,¹¹ and quinine intoxication.²³ A negative electroretinogram may be seen in early cases of retinitis pigmentosa²⁴ and rarely with other conditions: an overview has been presented recently by Weleber.¹⁵ With light adaptation, a negative electroretinogram can be found in the same disorders to a much lesser extent than with dark adapted conditions, with the exception of incomplete congenital stationary night blindness.¹⁴

Only a few cases with predominantly cone dysfunction and negative photopic electroretinogram have been mentioned in the literature.⁸⁻¹⁰ An overview of the clinical and electrophysiological findings in these patients is listed in Table 1 for easier comparison with our cases. The eight cases of Grey and Wakabayashi suffered from cone dystrophies.^{8,10} They had reduced visual acuity, colour vision defects, bull's eye lesions or pigment irregularities in the macula, and central or paracentral scotomas. The light rise of the electro-oculogram was either normal or reduced. The electroretinogram at dark adaptation was described as normal. Stimulus conditions are different and were not described in detail. Obviously much weaker stimuli were used. In our patients the reduction of the scotopic b-wave was better seen with higher stimulus intensities. These eight cases are comparable with our cases 1-3. In contrast to our series two of them were female. Young described another female patient with negative photopic electroretinogram without symptoms⁹; therefore she may be comparable with our case 4. In contrast to our patient she had widespread pigment clumping on the fundus and visual field defects, and a progression could be possible. Her dark adapted electroretinogram was reduced to about 50% with a normal b/a ratio.

In our series all five patients with clinical signs (cases 1-3, 5, and 6) had a dysfunction of the cones or the cone pathways. The visual acuity was reduced, colour vision defective, and in the electroretinogram the 30 Hz flicker response was reduced. The negative electroretinogram was more pronounced in all of our six cases with light adapted compared with dark adapted conditions. There was only one apparent difference in the electroretinographic waveforms between patients with cone dystrophies, incomplete congenital stationary night blindness, and X linked retinoschisis. In two patients with cone dystrophies (cases 2 and 3) only a PIII component with no detectable b-wave was found. A PIII component with no detectable b-wave can occur in incomplete congenital stationary night blind-

ness.¹³ In X linked retinoschisis a small b-wave is always present.¹⁸

The photopic electroretinogram is the result of cone responses, responses from depolarising and hyperpolarising bipolar cells from Müller cells, and possibly other retinal cell types. The a-wave corresponds to the beginning of the PIII component. The severely reduced b-waves indicate a disturbance in the proximal retinal layers either in the cone pathway or in the Müller cells. Similar electroretinographic findings as in our patients have been seen in rhesus monkeys in which APB (2-amino-4-phosphonobutyric acid) was injected intravitreally.²⁵ APB selectively blocks depolarising bipolar cells without affecting the hyperpolarising bipolar cells. In X linked retinoschisis histological findings indicate a defect of the Müller cells.²⁶

The inner retinal defect is not necessarily combined with the defect that causes receptor dysfunction. In case 3 the electroretinographic findings indicate receptor and inner retinal defects. The brother (case 4) had normal cone function, but showed a negative photopic electroretinogram. The cone dystrophy and the inner retinal defect, therefore, can be inherited separately.

Not all properties of the cone pathways are similar in our cases with cone dystrophies, and this may indicate different inner retinal defects. Interestingly, one of two patients with no measurable b-wave at light adaptation had a moderately reduced 30 Hz flicker amplitude of 60 μ V (case 3); the other one had no flicker response at all (case 2). The flicker response is generally regarded as the cone b-wave.²⁷ However, how can a flicker response persist when the b-wave is missing? Maybe the bipolar cells respond in a different way to flicker stimulation than to single flashes.

The findings in our patients indicate that additional inner retinal transmission defects in the cone pathway can occur in cone dystrophies. These patients present with reduced visual acuity, colour vision defects, a reduced 30 Hz flicker response, and a negative photopic electroretinogram. The most important differential diagnoses are incomplete congenital stationary night blindness and X linked congenital retinoschisis. The electroretinographic findings, however, do not allow a separation of these diseases. Diagnosis is only possible with evaluation of progression, funduscopic findings, and testing of dark adaptation.

- 1 Goodman G, Ripps H, Siegel I. Cone dysfunction syndromes. *Arch Ophthalmol* 1963; 70: 214-31.
- 2 Heckenlively JR. Cone dystrophies and dysfunction. In: Heckenlively JR, Arden GB, eds. *Principles and practice of clinical electrophysiology of vision*. St Louis: Mosby, 1991: 537-43.
- 3 Pinckers A, Deutman AF. Peripheral cone disease. *Ophthalmologica* 1977; 174: 145-50.
- 4 Yagasaki K, Jacobson SG. Cone rod dystrophy. Phenotypic diversity by retinal function testing. *Arch Ophthalmol* 1989; 107: 701-8.
- 5 Reichel E, Bruce AM, Sandberg MA, Berson EL. An electroretinographic and molecular genetic study of x-linked cone degeneration. *Am J Ophthalmol* 1989; 108: 540-7.
- 6 Kellner U, Foerster MH. Netzhautdegeneration mit Blauzapfenhypersensitivität. *Fortsch Ophthalmol* 1991; 88: 637-41.
- 7 Kellner U, Foerster MH. Color electroretinography - a method for separation of dysfunctions of cones. *Doc Ophthalmol* 1992; 80: 13-23.
- 8 Grey RHB, Blach RK, Barnard WM. Bull's eye maculopathy with early cone degeneration. *Br J Ophthalmol* 1977; 61: 702-18.

- 9 Young R, Price J, Gorham N, Cowart M. Selective abnormality of the cone b-wave in a patient with retinal degeneration. *Doc Ophthalmol* 1985; **60**: 211-8.
- 10 Wakabayashi K. Electrodiagnosis of primary macular dystrophies. *J Juzen Med Soc* 1986; **96**: 399-439.
- 11 Karpe G. The basis of clinical electroretinography. *Acta Ophthalmol* 1945; **24** (suppl): 1-118.
- 12 Schubert G, Bornschein H. Beitrag zur Analyse des menschlichen Elektroretinogramms. *Ophthalmologica* 1952; **123**: 396-413.
- 13 Miyake Y, Yagasaki K, Horiguchi M, Kawase Y, Kanda T. Congenital stationary night blindness with negative electroretinogram. A new classification. *Arch Ophthalmol* 1986; **104**: 1013-20.
- 14 Miyake Y. Incomplete type congenital stationary night blindness. In: Heckenlively JR, Arden GB, eds. *Principles and practice of clinical electrophysiology of vision*. St Louis: Mosby, 1991: 721-5.
- 15 Weleber RG, Pillers DAM, Powell BR, Hanna CE, Magenis RE, Buist NRM. Aland Island eye disease (Forsius-Eriksson syndrome) associated with contiguous deletion syndrome at Xp21. Similarity to incomplete congenital stationary night blindness. *Arch Ophthalmol* 1989; **107**: 1170-9.
- 16 Young RSL. Low-frequency component of the photopic ERG in patients with x-linked congenital stationary night blindness. *Clin Vis Sci* 1991; **6**: 309-15.
- 17 Hirose T, Wolf E, Hara A. Electrophysiological and psychophysical studies in congenital retinoschisis of x-linked recessive inheritance. *Doc Ophthalmol Proc Ser* 1977; **13**: 173-84.
- 18 Kellner U, Brümmer S, Foerster MH, Wessing A. X-linked congenital retinoschisis. *Graefes Arch Clin Exp Ophthalmol* 1990; **228**: 432-7.
- 19 Rhode N, Täumer R, Pernice D. Vorschlag eines verbesserten klinischen EOG-Testes. *Ber Dtsch Ophthalmol Ges* 1977; **74**: 747-50.
- 20 Foerster MH, Kellner U, Wessing A. Cone dystrophy and supernormal dark-adapted b-waves in the electroretinogram. *Graefes Arch Clin Exp Ophthalmol* 1990; **228**: 116-9.
- 21 Marmor MF, Arden GB, Nilsson SEG, Zrenner E. Standard for clinical electroretinography. *Arch Ophthalmol* 1989; **107**: 816-9.
- 22 Granit R. *Sensory mechanisms of the retina*. London: Oxford University Press, 1947.
- 23 Bacon P, Spalton DJ, Smith SE. Blindness from quinine toxicity. *Br J Ophthalmol* 1988; **72**: 219-24.
- 24 Krill AE. *Hereditary retinal and choroidal diseases*. Vol II. Hagerstown: Harper & Row, 1977: 403-4.
- 25 Smith EL, Harwerth RS, Crawford MLJ, Duncan GC. Contribution of the retinal ON channels to scotopic and photopic spectral sensitivity. *Vis Neurosci* 1989; **3**: 225-39.
- 26 Condon GP, Brownstein S, Wang NS, Kearns AF, Ewing CC. Congenital hereditary (juvenile x-linked) retinoschisis. Histopathologic and ultrastructural findings in three eyes. *Arch Ophthalmol* 1986; **104**: 576-83.
- 27 Birch DG. Flicker electroretinography. In: Heckenlively JR, Arden GB, eds. *Principles and practice of clinical electrophysiology of vision*. St Louis: Mosby, 1991: 348-51.