

Pars Plana Tube Insertion of Aqueous Shunt With Vitrectomy in Malignant Glaucoma

Medical treatment, laser surgery, and vitreous surgery have been useful options to treat aqueous misdirection (malignant glaucoma). Two patients with pseudophakic malignant glaucoma unresponsive to medical treatment underwent pars plana vitrectomy and tube shunt implantation through the pars plana. The outcome was favorable in both patients. The implantation of the

*For editorial comment
see page 799*

tube shunt through pars plana can help prevent recurrence of this condition by avoiding reaccumulation of fluid in the posterior segment of the eye, and can help in long-term control of intraocular pressure (IOP) in these glaucomatous patients.

"Aqueous misdirection" or "malignant glaucoma" is character-

ized by flattening of the anterior chamber without pupillary block or choroidal effusion or suprachoroidal hemorrhage, usually with an accompanying rise in IOP. To explain the pathogenesis of this condition, Shaffer¹ proposed that aqueous is diverted posteriorly toward the vitreous cavity. Medical treatment,² laser surgery,^{3,4} and vitreous surgery⁵⁻⁹ have all been useful options to treat this condition.

We report a new method of surgical treatment for malignant glaucoma, consisting of vitrectomy and tube shunt implantation through the pars plana.

Report of Cases. *Case 1.* An 86-year-old white woman was first seen in our service in September 1996 because of a shallow anterior chamber associated with episodes of high IOP in the right eye. The patient had had 2 Nd:YAG laser peripheral iridotomies after cataract extraction, which had been performed 6 years before coming to us. The IOP was quite labile despite medicinal treatment. The left eye was amblyopic and had developed "pupillary block"

after cataract extraction; a peripheral iridectomy had not helped control the IOP and the vision in the left eye had been lost.

On presentation, the visual acuity was 20/100 OD and no light perception in the left eye. The IOP was 42 mm Hg in the right eye and 12 mm Hg in the left. Treatment for the right eye was 2% dorzolamide hydrochloride thrice daily, 0.5% timolol maleate twice daily, 0.005% latanoprost at bedtime, and 50 mg of methazolamide orally twice daily, and treatment for the left eye was 1% prednisolone acetate twice daily and 1% atropine sulfate twice daily. The right eye had a shallow anterior chamber, 0.9 mm in depth (**Figure 1**). There were 2 patent peripheral iridotomies. The left eye had a deep anterior chamber. The anterior chamber angle was closed by peripheral anterior synechiae, 360° in both eyes. The optic disc of the right eye showed advanced glaucomatous cupping; the cupping was total in the left eye. Visual field examination of the right eye with a computerized perimeter (threshold strategy) revealed a severe constriction of the visual field, and with a marked depression of the retinal sensitivity in the arcuate areas. Ultrasound biomicroscopy ruled out ciliary or choroidal effusion or suprachoroidal hemorrhage.

Additional medical treatment was prescribed: 1% tropicamide 4 times daily, 1% atropine sulfate 4 times daily, and 2.5% phenylephrine hydrochloride 4 times daily. Topical and systemic aqueous suppressants were continued, but 24 hours later the anterior chamber depth and IOP were unchanged in the right eye. Neodymium:YAG laser capsulotomy was considered, but

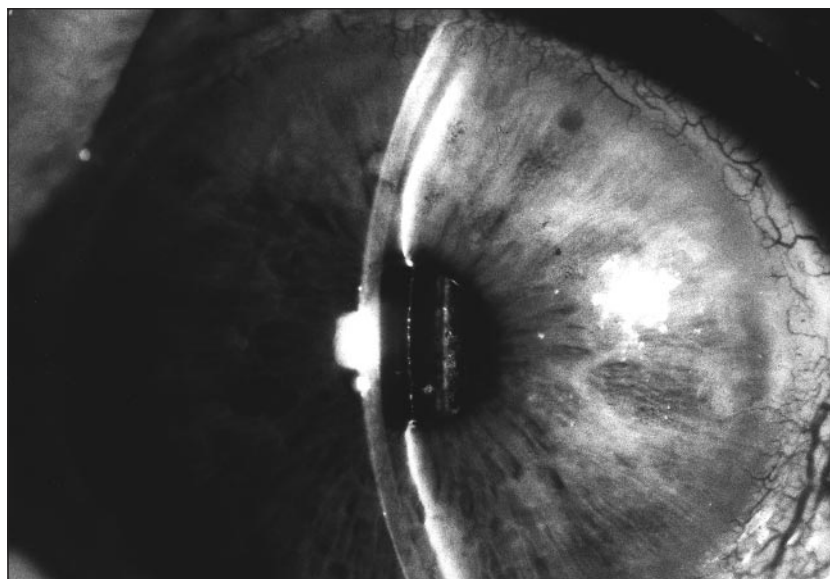


Figure 1. Slitlamp photograph of the right eye in case 1. The anterior chamber is very shallow. Two (patent) peripheral iridotomies are barely seen at the 10- and 1-o'clock positions.

*This article is also
available on our Web site:
www.ama-assn.org/ophth.*

believed unlikely to be of adequate immediate benefit. The severity of the glaucomatous damage and high IOP, which prompted an urgent and effective intervention, and the presence of peripheral anterior synchia in the anterior chamber angle, which would probably impede a satisfactory long-term control of IOP, were the factors considered in the surgical planning. The patient underwent a standard 3-port pars plana vitrectomy, removing the anterior vitreous and adhesions around the peripheral iridectomies; a Baerveldt (350 mm²) tube shunt was implanted through the pars plana. This surgical technique has been described elsewhere.⁵⁻⁹ During the procedure, the anterior chamber deepened. The postoperative outcome was uncomplicated (**Figure 2**). Six months later, the visual acuity in the right eye was 20/80, IOP was 13 mm Hg with no medical treatment, the anterior chamber was deep, and there was no apparent complication.

Case 2. A 72-year-old white woman developed pain and blurred vision in the left eye. She had previously had Nd:YAG laser peripheral iridectomies in both eyes and 2 weeks before coming to us had undergone an uncomplicated phacemulsification with posterior chamber intraocular lens implantation in the left eye. The visual acuity was 20/30 OD and counting fingers at 120 cm OS. The IOP was 15 mm Hg in the right eye and 48 mm Hg in the left. Treatment in the left eye consisted of 0.5% timolol maleate twice daily, 0.2% brimonidine tartrate thrice daily, 2% dorzolamide thrice daily, and 1% cyclopentolate hydrochloride twice daily. The right eye had a clear cornea, a moderately shallow anterior chamber, 2 patent iridectomies, and a moderately dense nuclear cataract. The cornea of the left eye had diffuse corneal edema and a very shallow central anterior chamber but without lens-corneal touch. Two patent iridectomies were present at the 12- and 2-o'clock positions. Gonioscopy with indentation revealed a closed anterior chamber angle. The retina was attached, without peripheral choroidal or retinal abnormalities. The optic disc had moderate glaucomatous damage. Visual field examination was not performed.

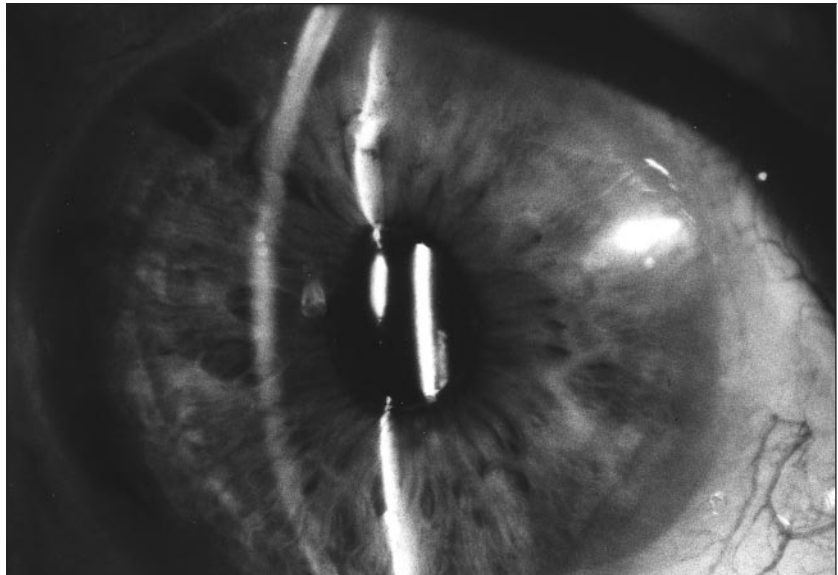


Figure 2. Slitlamp photograph of the same eye as in Figure 1 four weeks after surgery. The anterior chamber is deep. The temporal iridotomy has been enlarged.

The patient was treated with intravenous mannitol solution and oral acetazolamide; the current topical treatment was supplemented with 2.5% phenylephrine hydrochloride 4 times daily. The following day the corneal edema in the left eye persisted, the anterior chamber depth was unchanged, and the IOP was 29 mm Hg. Neodymium:YAG laser was not performed because of the lack of corneal clarity. The patient underwent a pars plana vitrectomy and a Baerveldt (250 mm²) tube shunt implantation. The tube tip was placed in the posterior segment through the pars plana. The anterior chamber deepened during the procedure. The postoperative period was uneventful. Four months after surgery in the left eye, the best-corrected visual acuity was 20/25, the anterior chamber was deep, and IOP was 10 mm Hg.

Comment. Malignant glaucoma or aqueous misdirection is initially managed with mydriatic-cycloplegic drops, aqueous suppressants, and hyperosmotics.² If medicinal therapy is unsuccessful, laser or surgical intervention is usually advised. Pars plana vitrectomy can be effective when other therapies fail, especially in pseudophakic and aphakic eyes.⁵⁻⁹ However, after resolving the attack of aqueous misdirection itself, the IOP can remain elevated or even increase due to other factors.

Chronic angle closure glaucoma and/or failure of previous filtering surgery can occur in cases of malignant glaucoma after successful pars plana vitrectomy: all 5 cases reported by Momoeda et al⁵ required medicinal treatment, and 2 of 5 patients required further filtration surgery after successful reversal of malignant glaucoma by pars plana vitrectomy, associated with intracapsular cataract extraction. The filtering bleb failed in 1 of the 2 patients with pseudophakic malignant glaucoma, which was treated by vitrectomy, as described by Lynch et al.⁶ Byrnes et al⁷ observed failure of the bleb after vitrectomy for ciliary block glaucoma in 4 of 19 cases. Harbour et al⁸ recently described 21 patients with malignant glaucoma treated with vitrectomy; 4 had postoperative visual loss due to progressive glaucoma.⁸

Although pars plana tube insertion with vitrectomy has been used to treat neovascular glaucomas and glaucomas associated with pseudophakia and aphakia,¹⁰⁻¹² to our knowledge, the use of this technique to treat malignant glaucomas has not been reported previously.

In the 2 patients described herein, prompt surgical intervention was indicated owing to the lack of response to the initial medicinal treatment, the level of IOP, the advanced glaucomatous damage (case 1), and the presence of corneal

edema (case 2). In patients without advanced glaucomatous damage, medical treatment should be tried for 2 to 4 days before surgical intervention, and, when possible, Nd:YAG laser treatment can be tried. The satisfactory postoperative outcome probably reflects the efficacy of pars plana vitrectomy in treating the aqueous misdirection and tube shunt implantation in controlling the IOP. It is also likely that the tube inserted through the pars plana will prevent recurrence of this condition. However, it is not known whether more prolonged medical therapy or pars plana vitrectomy without tube shunt implantation would have been sufficient.

We suggest that pars plana tube insertion with vitrectomy can be a useful technique to treat patients with malignant glaucoma and a closed anterior chamber angle. This technique can effectively relieve the aqueous misdirection. The implantation of the tube shunt through pars plana can help prevent recurrence of this condition, and can help in long-term control of IOP in glaucomatous patients. This technique appears to be especially appropriate for patients with moderate or severe glaucomatous damage.

Augusto Azuara-Blanco, MD, PhD
L. Jay Katz, MD
Sai B. Gandham, MD
George L. Spaeth, MD
Philadelphia, Pa

Dr Azuara-Blanco is now with Queen's Medical Centre, University of Nottingham, Nottingham, England.

Corresponding author: L. Jay Katz, MD, Wills Eye Hospital, 900 Walnut St, Philadelphia, PA 19107 (e-mail: ljk22222@aol.com).

1. Shaffer R. Role of vitreous detachment in aphakic and malignant glaucoma. *Trans Am Acad Ophthalmol Otolaryngol.* 1954;58:217-231.
2. Chandler PA, Simmons RJ, Grant EM. Malignant glaucoma: medical and surgical treatment. *Am J Ophthalmol.* 1968;66:495-502.
3. Herschler J. Laser shrinkage of the ciliary processes: a treatment for malignant (ciliary block) glaucoma. *Ophthalmology.* 1980;87:1155-1159.
4. Epstein DL, Steinert RF, Puliafito CA. Neodymium:YAG laser therapy to the anterior hyaloid in aphakic malignant (ciliary block) glaucoma. *Ophthalmology.* 1980;87:1155-1159.
5. Momoeda S, Hayashi H, Oshima K. Anterior pars plana vitrectomy for phakic malignant glaucoma. *Jpn J Ophthalmol.* 1983;27:73-79.
6. Lynch MG, Brown RH, Michels RG, Pollack IP, Stark WJ. Surgical vitrectomy for pseudophakic malignant glaucoma. *Am J Ophthalmol.* 1986;102:149-153.

7. Byrnes GA, Leen MM, Wong TP, Benson WE. Vitrectomy for ciliary block (malignant) glaucoma. *Ophthalmology.* 1995;102:1308-1311.
8. Harbour JW, Rubsamen PE, Palmberg P. Pars plana vitrectomy in the management of phakic and pseudophakic malignant glaucoma. *Arch Ophthalmol.* 1996;114:1073-1078.
9. Weiss H, Shin DH, Kollarits CR. Vitrectomy for malignant (ciliary block) glaucomas. *Int Ophthalmol Clin.* 1981;21:113-119.
10. Lloyd MA, Heuer DK, Baerveldt G, et al. Combined Molteno implantation and pars plana vitrectomy for neovascular glaucoma. *Ophthalmology.* 1991;98:1401-1405.
11. Gandham SB, Costa VP, Katz LJ, et al. Aqueous tube-shunt implantation and pars plana vitrectomy in eyes with refractory glaucoma. *Am J Ophthalmol.* 1993;116:189-195.
12. Varma R, Heuer DK, Lundy DC, Baerveldt G, Lee PP, Minckler DS. Pars plana Baerveldt tube insertion with vitrectomy in glaucomas associated with pseudophakia and aphakia. *Am J Ophthalmol.* 1995;119:401-407.

Acute Microcystic Corneal Epitheliopathy After Daily Soft Contact Lens Wear

We describe 4 patients who developed an acute bilateral microcystic corneal epitheliopathy with a marked reduction in visual acuity after using daily wear soft contact lenses. The cysts cleared over a period of 4 weeks with complete visual recovery, although 1 patient developed central corneal flattening. Examination of an epithelial biopsy specimen from 1 patient was negative for *Acanthamoeba*. However, apoptosis was demonstrated by staining with TUNEL (TdT-mediated dUTP nick-end labeling) assay. We believe that this phenomenon is the result of acute corneal hypoxia.

Epithelial microcysts are small (15- to 50- μ m) inclusions previously described as a delayed response to extended contact lens

wear.¹ They have been noted less frequently after daily wear soft or rigid contact lens wear. Patients using extended wear soft lenses typically develop microcysts after 4 to 8 weeks. The number of cysts that develop is related to the oxygen permeability of the lens and the duration of wear, and they take several months to disappear after discontinuation of lens wear. They typically occur in small numbers in the center or the mid-periphery of the cornea and rarely produce symptoms. In contrast, we describe 4 patients who wore daily wear soft contact lenses who developed an acute reduction in vision associated with a gross microcystic epitheliopathy. The clinical features and the possible origin of this condition are discussed.

Methods. Four patients who had worn daily wear soft contact lenses and who presented with an acute bilateral corneal microcystic epitheliopathy were identified (**Table**). When first examined, all were advised not to wear their contact lenses; they were then given a topical antibiotic (0.5% chloramphenicol 4 times a day for 1 week) and reviewed until resolution of the microcysts was complete. The first patient had an epithelial biopsy performed to exclude *Acanthamoeba* keratitis as the cause; part of the biopsy specimen was incubated on nonnutrient agar seeded with killed *Escherichia coli*, while the remainder was examined using a rabbit anti-*Acanthamoeba* monoclonal antibody. A TUNEL (TdT-mediated dUTP nick-end labeling) assay (Gibco BRL, Paisley, United Kingdom), which identifies dying

Characteristics of Patients With Acute Microcystic Corneal Epitheliopathy From Daily Wear Soft Contact Lenses

Patient No./ Age, y/Sex	Duration of Wear Prior to Onset, y	Cleaning System	Worst Visual Acuity*	Final Visual Acuity*
1/31/F	5	Isopropyl alcohol, polidronium chloride	-6/18+2 OD -6/12+2 OS	-6/5 OD -6/5 OS
2/25/F	2	Hydrogen peroxide	-1/60 OD -1/60 OS	-6/6 OD -6/6 OS
3/28/F	1	Polyquad	-2/60 OD -3/36 OS	-6/6 OD -6/6 OS
4/29/F	4	Hydrogen peroxide	-6/18 OS -6/36 OS	-6/6 OD -6/6 OS

*With spectacle correction.




Figure 1. Left, Clinical photograph of case 1 taken on the morning of the onset of symptoms. Note the large number of cysts that are almost confluent in the epithelium. Right, Clinical photograph of case 2 taken 3 days after the onset of symptoms. The peripheral cornea (inferior of photograph) is clear of cysts.

(apoptotic) cells by labeling fragmented DNA, was also performed.

Results. Two patients wore lenses on a regular basis and 2 only wore lenses for social occasions. All patients denied previous lens problems, overnight wear, or contact lens abuse. All had worn their lenses on the day before the onset of symptoms and, on waking, had noted a marked reduction in vision with only a mild foreign body discomfort.

First examinations were between 1 and 3 days of the onset of symptoms. Vision was reduced in all eyes and deteriorated further in 2 patients despite the discontinuation of contact lens wear (Table). All had mild conjunctival hyperemia, slight chemosis, but no anterior uveitis. In 2 patients the microcysts extended to the limbus, but in the 2 who were seen later, there was a peripheral ring of normal epithelium approximately 2 mm in diameter (**Figure 1**). There was only scattered punctate uptake of fluorescein by the epithelium. Central corneal thickness was normal, there were no stromal striae, and, after resolution, all patients had a normal endothelial cell structure with no signs of epithelial basement membrane disease. Peripheral corneal neovascularization was not present.

Resolution of the microcysts progressed centrally and all eyes were free of cysts within 4 weeks. Patient 3 developed a 2-mm-diameter epithelial erosion in one eye that healed without further symptoms. Patient 1 developed a bilateral faint subepithelial haze that had cleared by 4 weeks. This patient had keratometry readings in 1988 of (7.55

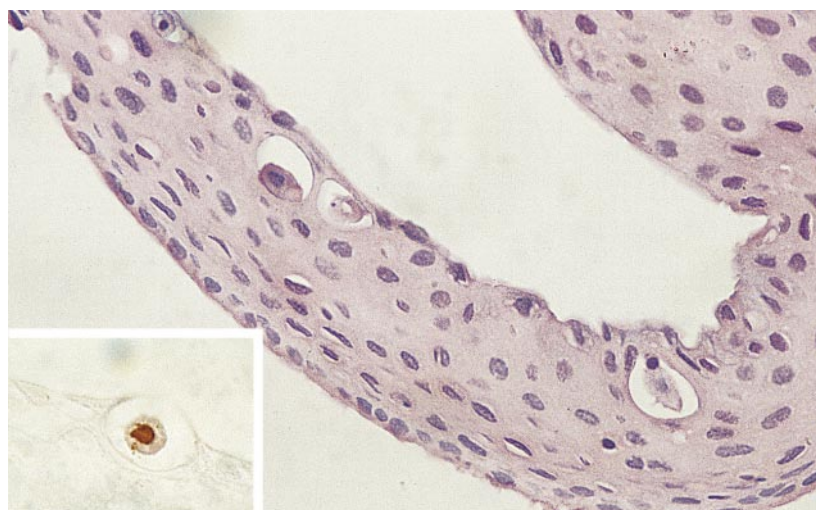


Figure 2. Photomicrograph of biopsy specimen taken from the corneal epithelium from case 1 that has folded such that the superficial surface is concave. Note the microcysts containing shrunken epithelial cells with condensed nuclear material (hematoxylin-eosin, original magnification $\times 60$). Insert, A single TUNEL (TdT-mediated dUTP nick-end labeling) assay-positive cell (original magnification $\times 75$).

mm at 180/7.60 at 090 OD; 7.60 mm at 180/7.75 at 090 OS) when she was first fitted with Permaflex (Wesley Jesson, PBH Ltd, Southampton, United Kingdom) lenses (8.70:14.40:–9.50 OD, 8.70:14.40:–8.50 OS) that she wore uneventfully for 5 years. Four weeks after we saw her, her myopia had reduced from –9.50/–0.75 at 015 OD; –8.75/–1.25 at 180 OS to –5.25/–1.00 at 050 OD; –3.75/–1.00 at 145 OS, and this refraction has been stable for 24 months. Her keratometry readings have not changed, but videokeratotomy demonstrated approximately 4 diopters of apical corneal flattening.

All patients have subsequently returned to contact lens wear. Patient 1 changed to daily wear rigid gas permeable contact lenses after 9 months without lenses, while the remainder have returned to daily

wear soft contact lenses with a recommendation that the daily wearing time does not exceed 8 hours. There has been no recurrence of symptoms after a minimum follow-up of 20 months.

Findings from examination of the corneal epithelial biopsy specimen were negative for *Acanthamoeba*. Histologic investigation showed superficial cysts containing shrunken epithelial cells with small condensed nuclei or fragments of nuclear material, often with dark homogeneous eosinophilic cytoplasm (**Figure 2**). The TUNEL assay revealed that a few of these cells had nuclei with cleaved DNA (Figure 2, insert).

Comment. The formation of corneal epithelial microcysts following extended contact lens wear is

thought to result from chronic hypoxia that leads to cell death and an accumulation of debris in intercellular pockets.¹ Increased metabolic activity after discontinuation of lens wear may then result in an increase in the number of microcysts that are then cleared by anterior migration from the epithelium.¹ Associated abnormalities, such as faint axial stromal infiltrates, are uncommon.²

We propose that acute corneal microcystic epitheliopathy is also a response to hypoxia. The reason for the sudden onset after a period of trouble-free lens wear is unclear and the mechanism of the apical corneal flattening in one patient is unexplained. A recent study of corneal epithelial cell shedding has shown that a few surface cells normally have fragmented DNA and that cell death, as defined by a calcein-ethidium viability assay, is a normal feature of corneal epithelial cell turnover.³ Hypoxia is a recognized cause of apoptosis,⁴ and it is possible that premature cell death beneath the epithelial surface contributed to the formation of microcysts in our patients.

Other causes of epithelial microcystic keratopathy were considered.⁵ However, none of our patients had features of an associated corneal dystrophy or endothelial failure, history of infection, surgery, or abrasion, and associated external eye disease. No chemical component of the contact lens care systems was common to all cases, although a non-specific toxic side effect cannot be excluded as a possible mechanism. Findings from the culturing and immunohistochemistry for *Acanthamoeba*, a further cause of epitheliopathy in contact lens wearers, were also negative. We therefore consider that hypoxia is the most likely cause and that the phenomenon may be a step on the way to contact lens-induced epithelial necrosis.

Stephen J. Tuft, MD, FRCOphth
Philip Luthert, FRCPath
London, England

The rabbit anti-Acanthamoeba monoclonal antibody was a gift from Simon Kilvington, PhD, Public Health Laboratory, Bath, England.

Corresponding author: Stephen J. Tuft, MD, FRCOphth, Moorfields Eye Hospital, London EC1V 2PD, England (e-mail: stuft@compuserve.com).

1. Holden BA, Sweeney DF. The significance of the microcystic response: a review. *Optom Vis Sci.* 1991;68:703-707.
2. Kenyon E, Polse KA, Seger RG. Influence of wearing schedule on extended-wear complications. *Ophthalmology.* 1986;93:231-236.
3. Ren H, Wilson G. Apoptosis in the corneal epithelium. *Invest Ophthalmol Vis Sci.* 1996;37:1017-1025.
4. Shimizu S, Eguchi Y, Kamiike W, et al. Induction of apoptosis as well as necrosis by hypoxia and predominant prevention of apoptosis by Bcl-2 and Bcl-XL. *Cancer Res.* 1996;56:2161-2166.
5. Bron AJ, Tripathi RC. Cystic disorders of the corneal epithelium, I: clinical aspects. *Br J Ophthalmol.* 1973;57:361-375.

Repair of a Complex Retinal Detachment With Proliferative Vitreoretinopathy in an Eye With Extreme Scleral Thinning

The repair of complicated retinal detachments (RDs) entails substantial mechanical stresses on the globe due to ocular rotation for exposure, elevated intraocular pressure with infusion fluids and tamponades, and scleral alterations with buckling. We successfully repaired a total RD with grade C proliferative vitreoretinopathy in an eye with extreme scleral attenuation by strengthening the sclera prior to vitrectomy without the use of scleral buckling.

Report of a Case. A 60-year-old man with a phthisical left eye due to an unrepaired RD after cataract surgery 10 years earlier was referred with a total RD in his right eye. Three years prior to being referred to us, the patient had undergone uneventful extracapsular cataract surgery with posterior chamber intraocular lens implantation in the right eye. Nine months later, a rhegmatogenous RD was successfully repaired using an encircling silicone sponge exoplane with visual recovery to 20/70. Six months prior to examination, a *Staphylococcus epidermidis* buckle infection necessitated removal of the exoplane, with redetachment 6 days later. Despite successful treatment with systemic antibiotics and ste-

roids, severe temporal scleral thinning developed (**Figure 1**). There were no signs of external inflammation or active scleritis, and there was no clinical or laboratory evidence of collagen vascular disease. On examination, visual acuity was hand motions and results of funduscopic examination revealed marked vitreous debris and a total RD with grade C proliferative vitreoretinopathy.

At surgery, placement of the eyelid speculum alone provoked ectasia of the temporal sclera with impending rupture. An 18 × 10-mm full-thickness donor scleral patch graft was placed over the thinned area and sutured to healthy sclera along its edges (**Figure 2**). Immediately, a 3-port pars plana vitrectomy was performed. Following vitreous removal, extensive preretinal and subretinal fibrous proliferation surrounding an inferotemporal peripheral retinal break was identified. The retina was reattached by membrane peeling, relaxing retinotomy for 3 clock hours, and perfluorocarbon liquid (Perfluoron, Infinitect, Chesterfield, Mo). Endolaser retinopexy was performed, the perfluorocarbon liquid exchanged for air, and the air exchanged for 16% perfluoropropane gas. It was not possible to completely cover the scleral graft by mobilizing conjunctiva; 1 week later, a free conjunctival autograft from the contralateral eye was placed over the exposed sclera.

At the last examination, 6 weeks after vitrectomy, the visual acuity was 20/500. While necrosis of the conjunctival autograft had necessitated its excision 2 weeks earlier, vascularization of the healthy-appearing scleral patch was evident (**Figure 3**). The retina was completely reattached and there were no signs of recurrent proliferative vitreoretinopathy. At no time during the postoperative period was control of intraocular pressure a problem.

Comment. Donor sclera is commonly used to cover ectatic areas of sclera in patients with inflammatory diseases, wrap orbital implants, cover glaucoma seton hardware, support extremely thin eye walls prior to scleral buckling,¹ and

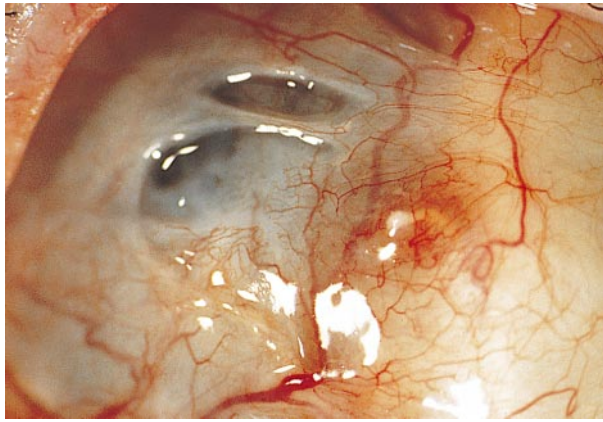


Figure 1. Severe superotemporal scleral thinning present 1 month after removal of an infected scleral buckle.

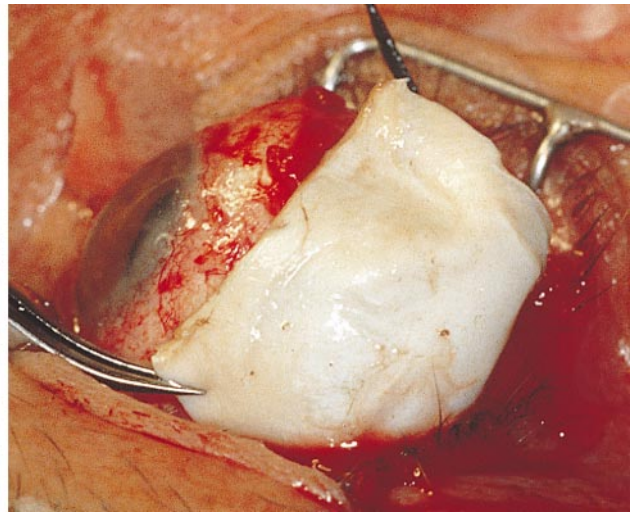
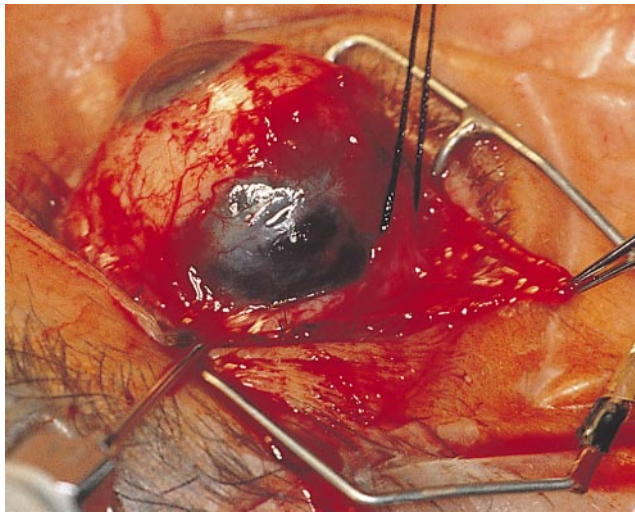


Figure 2. Left, Intraoperative exposure of a large region of drastically attenuated sclera prior to patching. Right, An 18 × 10-mm donor scleral graft being sized to cover the area of missing eye wall.

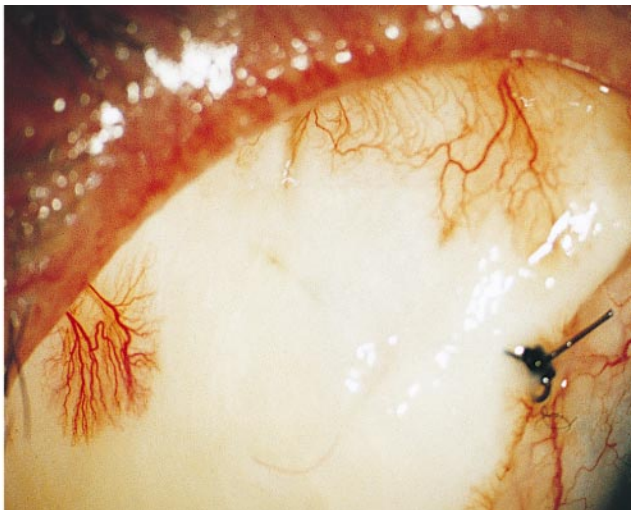
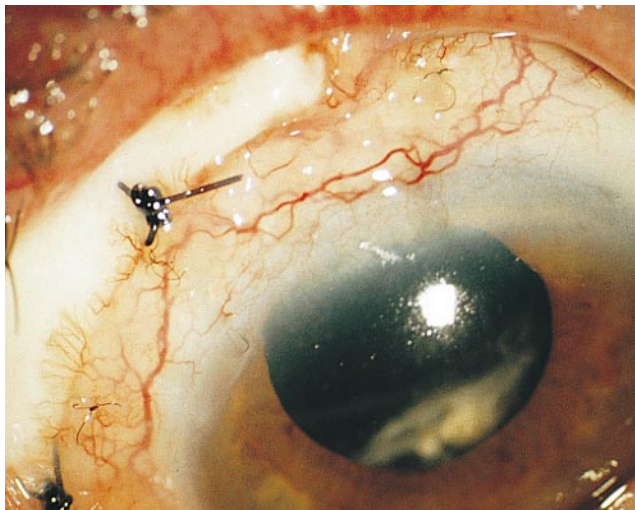


Figure 3. Left, Well-positioned scleral patch graft, 6 weeks after vitrectomy. The conjunctival autograft had necrosed and been removed by this time. Right, Early vascularization of the scleral patch has begun.

cover explants that have become exposed.^{2,3} Although the conjunctival autograft became necrotic despite aggressive management with 1% topical progesterone drops, the

scleral graft appears to be surviving and the importance of conjunctival covering remains unclear.⁴

Intraoperative trauma and postoperative activity posed a serious risk

of globe rupture in this one-eyed patient with a defect of almost one third of the eye wall. Reinforcement by placement of a scleral patch permitted successful repair of a complex

RD using vitrectomy techniques that did not cause scleral buckling.

Panagiotis G. Theodossiadis, MD
Donald J. D'Amico, MD
Boston, Mass

David J. Weissgold, MD
Burlington, Vt

Reprints: Donald J. D'Amico, MD,
Retina Service, Massachusetts Eye &
Ear Infirmary, 243 Charles St, Bos-
ton, MA 02114-3096.

1. Wilson RS, Parker JC. Scleral patch for exposed silicone buckles. *Ophthalmic Surg.* 1975;6:83-85.
2. Regenbogen L, Romano A, Zuckerman M, Stein R. Histoacryl tissue adhesive in some types of retinal detachment surgery. *Br J Ophthalmol.* 1976; 60:561-564.
3. Watzke RC. Scleral patch graft for exposed episcleral implants. *Arch Ophthalmol.* 1984;102: 114-115.
4. de la Maza MS, Tauber J, Foster CS. Scleral grafting for necrotizing scleritis. *Ophthalmology.* 1989; 96:306-310.

Parafoveal Telangiectasia in Association With CREST Syndrome

Parafoveal telangiectasia has been described as a developmental or acquired vascular anomaly of the foveal avascular zone characterized by irregular capillary dilatation, serous exudation, and macular edema.¹ The acquired form of this anomaly has been termed *idiopathic juxtafoveal retinal telangiectasia* and its etiology has not been established.² Gass has divided this disorder into 3 groups based on ease of visibility of

the telangiectatic vessels, presence of retinal exudation, and degree of capillary occlusion.¹ We present a case that, to the best of our knowledge, is the first description of parafoveal telangiectasia seen in association with the syndrome of calcinosis cutis, Raynaud phenomenon, esophageal dysmotility, sclerodactyly, and telangiectasia (CREST syndrome).

Report of a Case. In 1986, a 61-year-old white woman was seen by her general practitioner with symptoms indicative of the Raynaud phenomenon affecting both hands. Cutaneous erythema and telangiectatic vessels were observed and the facial skin had a foreshortened appearance with resulting tightness. From these features a diagnosis of scleroderma was established. Approximately 4 years after her initial diagnosis, she developed gastric motility symptoms consisting of dyspepsia and dysphagia. In January 1997, she complained of decreasing vision in her right eye. Examination by her ophthalmologist revealed macular edema and a retinal consultation was obtained. Examination at that time disclosed a visual acuity of 20/200 OD and 20/20 OS. Slitlamp examination results and intraocular pressure were unremarkable. Dilated fundus examination revealed telangiectatic vessels in both maculae with mild retinal thickening seen in the temporal parafoveal region (**Figure 1**). No evidence of diabetic retinopathy was seen. Fluorescein angiography disclosed a characteristic appearance of late

staining involving the temporal hemifovea of both eyes, while the right macula displayed evidence of marked enlargement of the foveal avascular zone with an irregular "moth-eaten" appearance (**Figure 2**). No intraretinal crystals were noted. On general examination, dermal characteristics of scleroderma were noted on her face, extremities, and chest; sausage-like thickening of her fingers was also observed.

Comment. Although relatively uncommon, CREST syndrome consists of easily identifiable symptoms. Systemic vascular changes are responsible for the telangiectatic vessels, which seem to affect several systems within the body. These vascular abnormalities have been noted in the skin and gastric mucosa,³ but to date have not been identified with retinal findings. However, it is reasonable to suggest that such widespread vascular change could present itself in the eye. Our examination of the patient's retina and the discovery of parafoveal telangiectasia, in the absence of diabetic retinopathy or other causative factors, supports this argument and is important in identifying a potential systemic association. This finding is an important consideration for patients with scleroderma, who may also be seen with unexplained loss of vision.

According to the Gass classification,¹ our patient would be categorized as group 3A. Similar cases have been described in the literature with systemic associations dif-

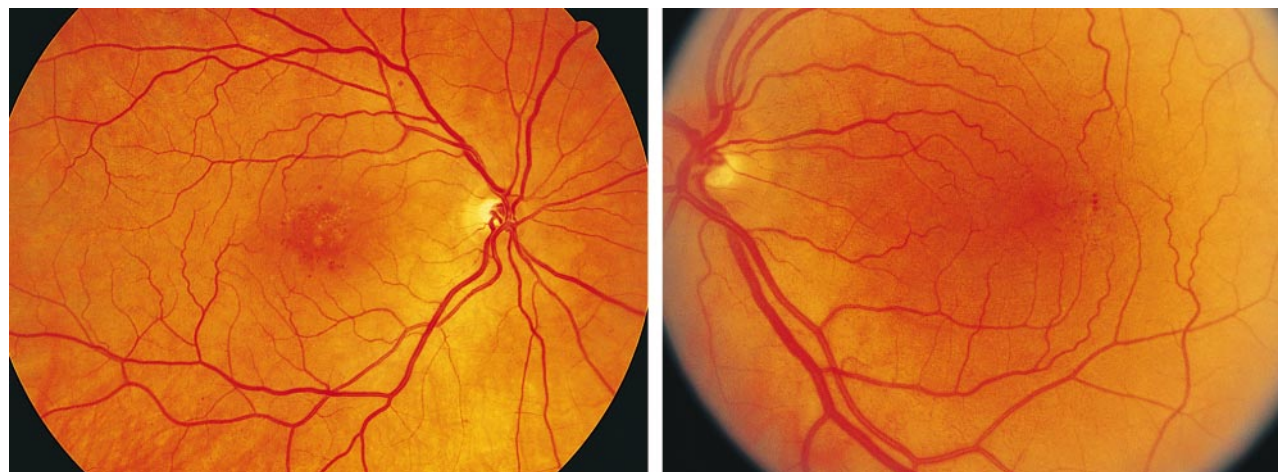


Figure 1. Demonstration of parafoveal telangiectatic changes in the right (left) and left (right) eye.

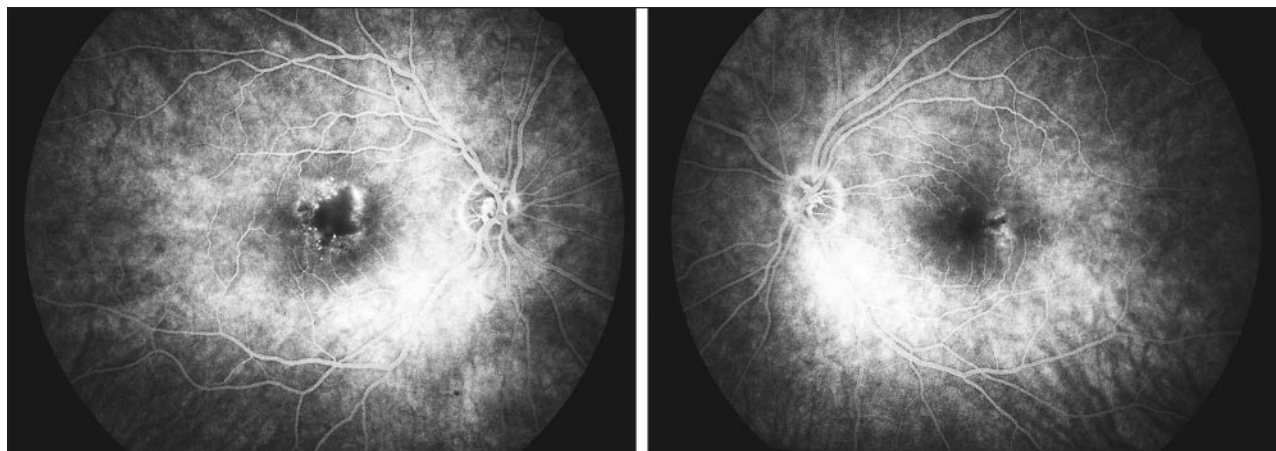


Figure 2. Left, Midframe fluorescein angiography of right macula. Note evidence of leakage from telangiectatic vessels in parafoveal location in addition to enlargement of foveal avascular zone. Right, Midframe fluorescein angiography of left macula demonstrating staining in the temporal hemifovea.

ferent from ours. Grand et al² have identified a hereditary syndrome in which retinal telangiectasia with capillary nonperfusion is associated with frontoparietal lobe pseudotumor. The histopathologic features of the central nervous system lesions included unusual vasculopathy and necrosis of white matter.² Lim and Bressler⁴ have reported a case of group 3A parafoveal telangiectasia associated with marked peripheral ischemia. Our patient did not display central nervous system dysfunction or peripheral retinal ischemia.

The presence of both juxtafoveal telangiectasia and CREST syndrome in our patient suggests a possible common pathophysiologic basis for the 2 diseases. Investigation of more patients will assist in establishing this association.

Brad Proctor, BSc
Tom Chang, MD, FRCSC
Dawn Hay, RN
Vancouver, British Columbia

Corresponding author: Tom Chang, MD, FRCSC, Section D, 2550 Willow St, Vancouver, British Columbia, Canada V5Z 3N9.

1. Gass JD, Oyakawa RT. Idiopathic juxtafoveal retinal telangiectasis. *Arch Ophthalmol.* 1982;100:769-780.
2. Grand MG, Kaine J, Fulling K, et al. Cerebroretinal vasculopathy; a new hereditary syndrome. *Ophthalmology.* 1988;95:649-659.
3. Binford R. CRST syndrome with gastrointestinal bleeding. *Arch Dermatol.* 1968;97:603-604.
4. Lim JJ, Bressler NM. Atypical parafoveal telangiectasis with subsequent anterior and posterior segment neovascularization. *Retina.* 1992;12:351-354.

Low-Dose External Beam Irradiation for Bilateral Diffuse Choroidal Hemangioma

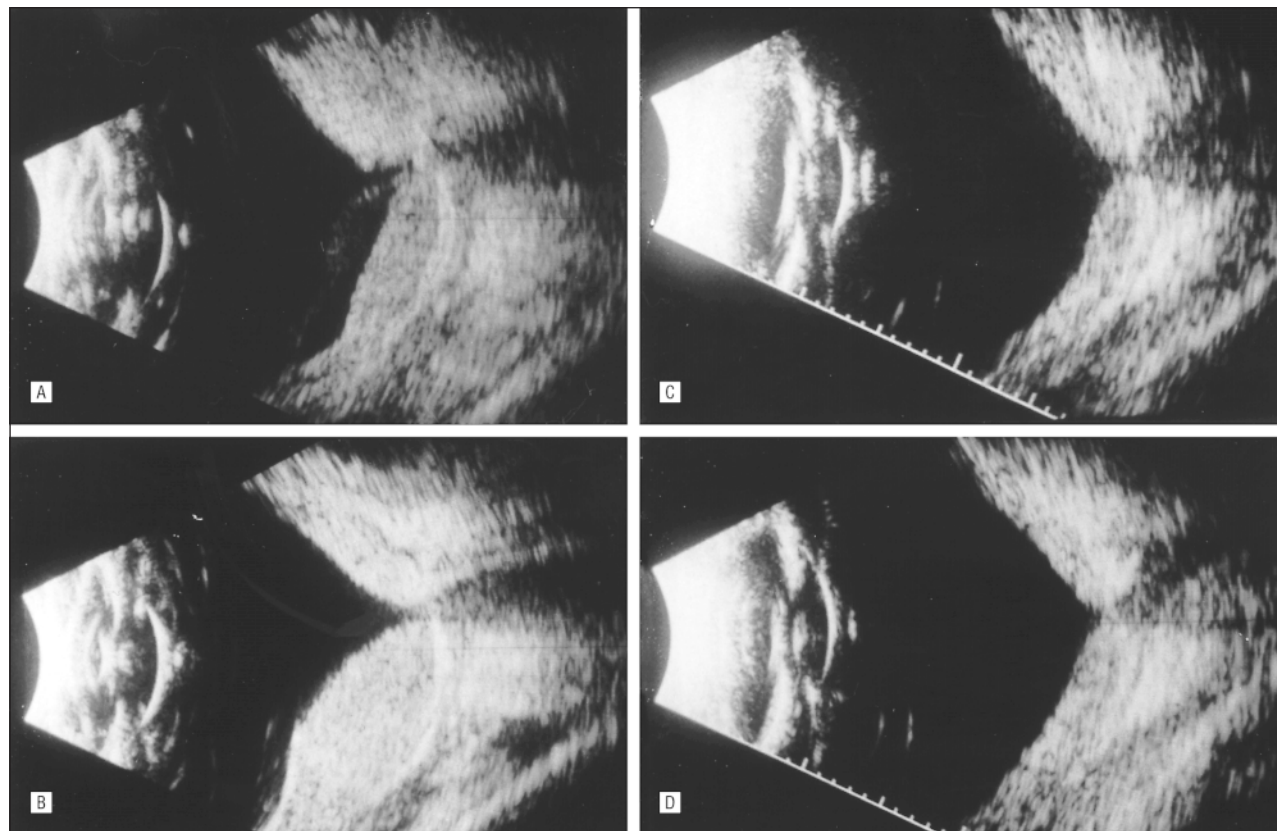
The diffuse choroidal hemangioma is an uncommon congenital vascular tumor associated with the Sturge-Weber syndrome.¹ Visual loss is often secondary to nonrhegmatogenous retinal detachments, cystoid degeneration, photoreceptor loss, and fibrous transformation of the proliferated retinal pigment epithelium.¹ The use of low-dose external beam irradiation has been reported as a possible treatment for nonrhegmatogenous retinal detachments associated with diffuse choroidal hemangioma.² We describe a patient with Sturge-Weber syndrome, bilateral diffuse choroidal hemangiomas, and nonrhegmatogenous serous retinal detachments treated with low-dose external beam irradiation.

Report of a Case. An 8-year-old girl with bilateral facial nevus flammeus was examined at the Bascom Palmer Eye Institute, Miami, Fla, for progressive visual loss in her left eye of 8 days' duration. Six months previously, she had developed an exudative detachment in her right eye with decreased visual acuity to the 20/400 level.

Examination revealed a facial angioma involving the right forehead and eyelid, cheek, and nose and

crossing to the nose and upper eyelid of the left side. Visual acuity measured 20/400 OD and could not be improved with refraction. Visual acuity was 20/80 OS and improved to 20/60 with +2.50+0.50×70°. The anterior segments and intraocular pressures were normal. Funduscopic examination of the right eye revealed a diffuse reddish hue and massive choroidal thickening that was most prominent in the posterior pole. A retinal fold was present through the papillomacular bundle with hyperplastic and metaplastic changes in the retinal pigment epithelium surrounding the optic nerve and in the macula. A serous detachment of the retina was present inferiorly with a pocket of fluid overlying the macula. In the left eye, an even greater degree of choroidal thickening was associated with a bullous detachment of the inferior retina and a shallow detachment of the macular region. No significant retinal pigment epithelial changes were noted ophthalmoscopically.

B-scan ultrasonography measured the choroidal thickness as 8 mm in the macula of the right eye and 6 mm in the left eye. A simultaneous A-scan revealed the tumor to be of high reflectivity. Fluorescein angiography showed rapid filling and marked extravasation of fluorescein dye from the retinal and choroidal vessels. Staining of the peripapillary retinal pigment epithelial hyperplastic changes was noted in the right eye, while in the left eye there was a C-shaped area of



A, Horizontal axial B-scan echogram of the right eye shows a diffuse, highly elevated choroidal lesion with bullous retinal detachment. B, Horizontal axial B-scan echogram of the left eye shows a diffuse, highly elevated choroidal lesion with very shallow retinal detachment. C and D, Follow-up B-scan echograms of the right (C) and left (D) eyes show markedly decreased elevation of choroidal hemangiomas with resolution of retinal detachments.

fluorescein staining at the level of the retinal pigment epithelium extending temporally from the inferior portion of the macula.

Because of the extensive diffuse nature of the choroidal hemangiomas, low-dose external beam radiation therapy was recommended. The patient underwent an uncomplicated course of external beam radiation therapy to both eyes to a total dose of 20 Gy (10 fractions of 200 Gy over 10 days).

Follow-up 3 months after radiation therapy revealed complete resolution of the exudative detachments in each eye. The choroidal thickening appeared decreased with moderate retinal pigment epithelial mottling of the posterior pole in the right eye. Visual acuity had improved to 20/50 OS and remained stable in the right eye. B-scan ultrasonography revealed a choroidal thickening of 3.0 mm OU (**Figure**).

At 11 months after radiation therapy, visual acuity measured 20/300 OD and 20/40+2 OS. Intraocular pressures were normal. The vi-

sual field in the left eye was full with enlargement of the blind spot temporally, while in the right eye there was superior constriction. There was no evidence of irradiation complications. There was no recurrence of serous exudation in either eye. The choroid measured less than 2 mm in each eye by ultrasonographic examination.

Twenty months after radiation therapy, visual acuity was 20/200 OD and 20/30+1 OS. Lenses remained clear and there was no evidence of recurrence of the choroidal thickening or serous exudation.

Comment. To our knowledge, this is only the second case of bilateral diffuse choroidal hemangiomas associated with bullous serous retinal detachments to be treated by low-dose external beam irradiation. Among the 4 patients described by Scott et al² treated with low-dose ocular irradiation for diffuse choroidal hemangioma was 1 patient who had evidence of bilateral disease. However, he had been previously treated on

multiple occasions with xenon arc photocoagulation prior to undergoing radiation therapy when his second eye became affected.

Since the initial report of Scott et al, 2 additional reports have described successful treatment of both unilateral diffuse choroidal hemangiomas associated with the Sturge-Weber syndrome and circumscribed choroidal hemangiomas with the use of lens-sparing low-dose external beam irradiation.^{3,4} Schilling et al³ treated 15 unilateral cases of diffuse choroidal hemangiomas with complete resolution of subretinal fluid in all cases, tumor mass shrinkage in 5 cases, and the improvement of vision in 7 eyes. Madreperla et al⁴ report their experience with 5 unilateral cases in which subretinal fluid was resorbed in all patients by 1 year after radiation therapy. They report improvement of the intraocular pressure after irradiation in 1 patient who had an elevated intraocular pressure.⁴

The occurrence of bilateral choroidal hemangiomas associated with

bilateral facial nevus flammeus is rare.⁵ The treatment of eyes with diffuse choroidal hemangioma that develop bullous nonrhegmatogenous detachments is very difficult. These lesions generally do not respond well to the modalities commonly used to treat circumscribed choroidal hemangiomas.⁶ Another less common form of treatment that appears effective in the treatment of choroidal hemangiomas associated with exudative detachment is brachytherapy.^{4,7} Zografos et al⁷ report the successful treatment of 2 diffuse choroidal hemangiomas in which a 15-mm radioactive plaque was placed "in the presumed center of the tumor." Although the authors report successful resolution of associated serous detachment in each case, they conclude that this technique cannot be recommended in patients with diffuse choroidal hemangiomas.⁷

The treatment of exudative detachments secondary to diffuse choroidal hemangiomas with low-dose fractionated ocular irradiation appears promising. In this case, such treatment was safe and effective for the short term. The potential complications include cataract formation, keratitis sicca, radiation papillopathy, and radiation retinopathy.⁸ With follow-up of 20 months, our patient showed an impressive resolution of the massive thickening of the choroid (8 mm to 3 mm), resolution of the associated serous detachments without evidence of recurrence, and an improvement of the vision in both eyes. We can only speculate whether earlier treatment of the right eye may have resulted in preservation of better vision in that eye. At this time she shows no complications attributable to the radiation therapy, although longer term follow-up may reveal such complications.

Justin L. Gottlieb, MD
Timothy G. Murray, MD
J. Donald M. Gass, MD
Miami, Fla

This research was supported in part by an American Cancer Society award, Tampa, Fla (Dr Murray), Fight for Sight, Schaumburg, Ill (Dr Murray), and a Stanley Glaser Award, Miami, Fla (Dr Murray).

Reprints: Justin L. Gottlieb, MD, Department of Ophthalmology, University of Wisconsin, 2870 University Ave, Suite 206, Madison, WI 53705 (e-mail: Gottlieb@eye.wisc.edu).

1. Witschel H, Font RL. Hemangioma of the choroid: a clinicopathologic study of 71 cases and a review of the literature. *Surv Ophthalmol.* 1976;20:415-431.
2. Scott TA, Augsburger JJ, Brady LW, Hernandez C, Woodleigh R. Low-dose ocular irradiation for diffuse choroidal hemangiomas associated with bullous nonrhegmatogenous retinal detachment. *Retina.* 1991;11:389-393.
3. Schilling H, Sauerwein W, Limmatsch A, et al. Long-term results after low-dose ocular irradiation for choroidal haemangiomas. *Br J Ophthalmol.* 1997;81:267-273.
4. Madreperla SA, Hungerford JL, Plowman PN, Laganowski HC, Gregory PTS. Choroidal hemangiomas: visual and anatomic results of treatment by photocoagulation or radiation therapy. *Ophthalmology.* 1997;104:1773-1778.
5. Lindsey PS, Shields JA, Goldberg RE, Augsburger JJ, Frank PE. Bilateral choroidal hemangiomas and facial nevus flammeus. *Retina.* 1981;1:88-95.
6. Shields JA, Shields CL. *Intraocular Tumors: A Text and Atlas.* Philadelphia, Pa: WB Saunders Co; 1992:254-255.
7. Zografos L, Bercher L, Chamot L, Gailloud C, Raimondi S, Egger E. Cobalt-60 treatment of choroidal hemangiomas. *Am J Ophthalmol.* 1996;121:190-199.
8. Sagerman RH, Chung CT, Alberti WE. Radiosensitivity of ocular and orbital structures. In: Alberti WE, Sagerman RH, eds. *Radiotherapy of Intraocular and Orbital Tumors.* Berlin, Germany: Springer-Verlag; 1993:375-385.

Electrophysiologic Evaluation of a Patient With Peripheral Visual Field Contraction Associated With Vigabatrin

Anticonvulsants are known to cause different kinds of visual disturbances.¹ Recently, vigabatrin has received attention because of considerable bilateral concentric field defects observed in a few patients receiving this drug as add-on therapy.² These field constrictions appear to be irreversible in most cases. Surprisingly, only subtle changes of retinal function have been reported, most often alterations of the oscillatory potentials in the electroretinogram (ERG). Findings from histopathological studies in rats, mice, and dogs but not in monkeys and humans show a microvacuolation in myelin sheaths of the white matter when exposed to vigabatrin.³ However, all these alterations cannot sufficiently explain a severe concentric visual field constriction.

Report of a Case. A 17-year-old boy suffered from focal epilepsy of unknown origin since the age of 13. Following unsuccessful treatment with carbamazepine and valproate as monotherapy and polytherapy, he was put on a combination regimen of valproate and vigabatrin 18 months prior to our first examination (2 g of vigabatrin and 2.4 g of valproate per day). One year later, the patient became aware of a constriction of his visual field.

Figure 1, A, shows the visual field constriction (Goldmann kinetic perimetry). The results of the static perimetry were comparable (Figure 1, C). Findings for visual acuity (20/20 OU), motility, eye position, anterior segments, and fundus were completely normal. Color vision tested by the desaturated Panel D-15 test, absolute rod threshold after 30 minutes of dark adaptation (Hartinger dark adaptometer, Carl Zeiss, Jena, Germany), and pattern evoked visual potentials were also unremarkable. Baseline and light peak of the electro-oculogram (ISCEV standard) also rendered normal results (Arden ratio, 2.1 OD, 1.9 OS).

The Ganzfeld electroretinogram (ERG) performed according to the International Society for Clinical Electrophysiology of Vision (ISCEV) standard was basically normal. The *b/a* ratio was low (1.2; normal ratio, 1.39 (SD, 0.12) and the amplitude of the second oscillatory potential was 31 μ V compared with a normal value of 76 μ V (SD, 18). While the rod and maximal b-wave amplitudes fell within the center of the normal range, the cone and 30-Hz flicker responses were at the lower border. In the multifocal ERG there were local responses of normal amplitude (ie, the difference between positive peak and negative trough) and implicit time even in areas of missing perception for the Goldmann target III/4 (**Figure 2, C**). In contrast, the multifocal ERG of the patient with retinitis pigmentosa who had a comparable visual field constriction shows the typical decrease of amplitude and increase of implicit time in the affected regions (Figure 2, B and D).⁴ However, the wave form in the affected areas of the patient receiving treatment with vigabatrin was different

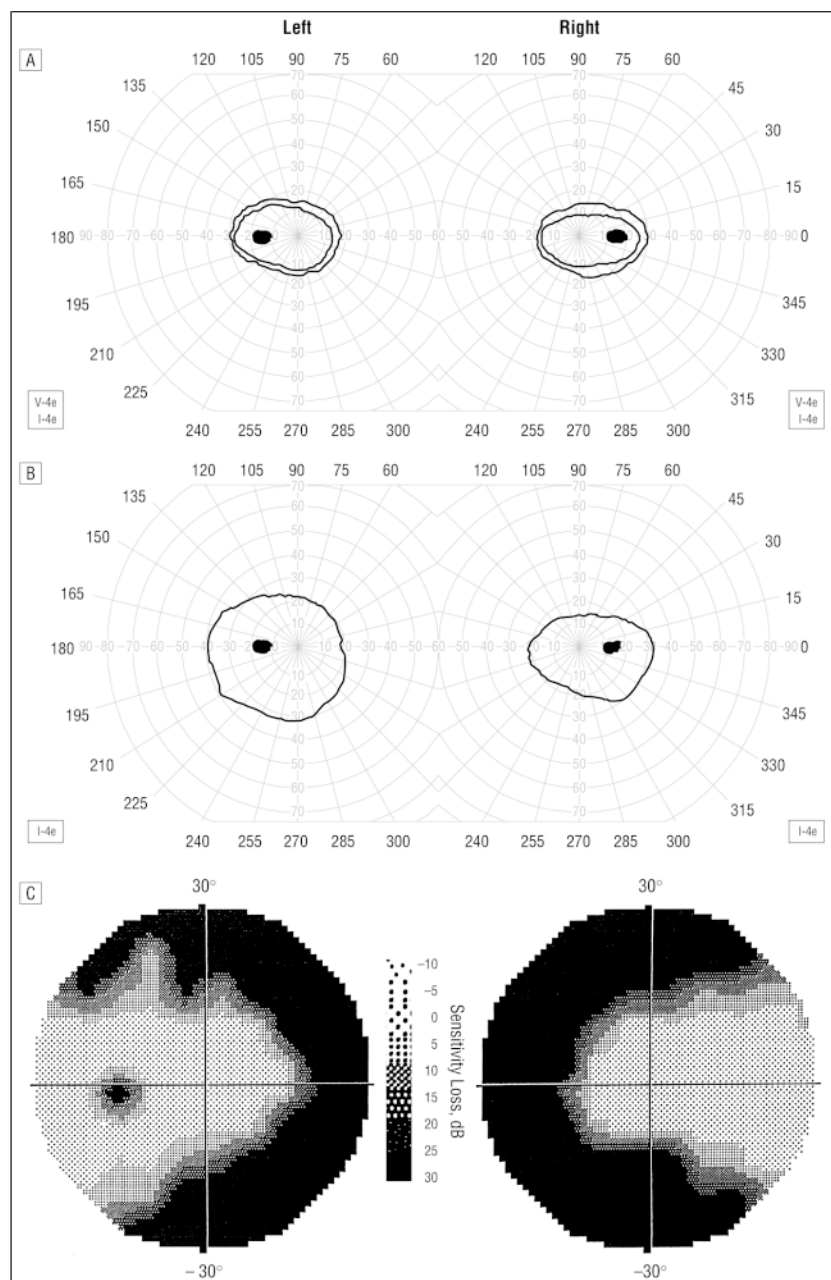


Figure 1. Goldmann kinetic visual fields of the patient taking vigabatrin (A) and a patient with retinitis pigmentosa (B). In part B, an additional isopter (V-4e) is displayed to illustrate that the difference between the sensitivity for bigger (V-4e) and smaller (I-4e) stimuli is rather small in the patient receiving treatment with vigabatrin. C, A 30° static perimetry of the patient receiving vigabatrin (Octopus perimeter 500 EZ, Interzeag, Schlieren, Switzerland), program 36; the missing blind spot in the visual field of the right eye is due to the rather coarse pattern of test stimuli (6°).

in that the positive peak was low compared with the preceding negative trough (Figure 2, A, arrows).

The ERG-off response (red light, 200-millisecond stimulus duration) was present, but the implicit time was late (230 milliseconds; normal response time, 225.6 milliseconds (SD, 1.95 milliseconds)). The scotopic threshold response was normal. Readings from the transient and steady state pat-

tern ERGs according to the ISCEV guidelines were normal for the central visual field. In contrast, stimulating the temporal retina where 50% of the pattern stimulus was displayed in the visual field loss area, the N95 component of the transient pattern ERG became smaller than the P50 component (about 70% of the P50 component) that never occurred in a normal observer.

Treatment with vigabatrin was immediately discontinued when the visual field defect was diagnosed. At the follow-up examinations the patient sometimes indicated a subjective improvement, but even 6 months after the first examination, the visual field contraction tested by kinetic and static perimetry remained the same.

Comment. In the case reported herein, the concentric visual field loss is probably due to the intake of vigabatrin because (1) the intake of carbamazepine which is known to interact with retinal function was ceased 12 months prior to the first symptoms of visual field constriction; (2) we are unaware of retinal toxic side effects associated with valproate treatment; and (3) the frequency and severity of seizures were low and therefore probably not affecting visual function. Comparing the multifocal ERG to that of a patient with retinitis pigmentosa shows that the outer retina is probably not the site of disease action. As in other reports, the oscillatory potentials of the Ganzfeld ERG were attenuated in our patient. Together with the selective reduction of the N95 component in the pattern ERG, there is evidence of an alteration of inner retinal function.

Vigabatrin is an aminobutyrate-aminotransferase antagonist and acts as a GABA (γ -aminobutyric acid) analog.⁵ GABA is a transmitter at different sites of the postreceptoral retina.⁶ It plays a role in the regulation of horizontal cell coupling, and an accumulation of GABA can be found in amacrine cells. The visual field constriction might result from a block of transmission between bipolar cells and amacrine and/or ganglion cells. Another possibility might be a loss of ganglion cell function. If so, the high redundancy of information-processing in the central retina may be the reason for sparing of the central visual field. Another explanation could be that vigabatrin is eventually more toxic to peripheral than to central ganglion cells. In any case, ganglion cell damage may lead to optic atrophy in later stages of the disease which has already been reported in other cases of visual field constric-

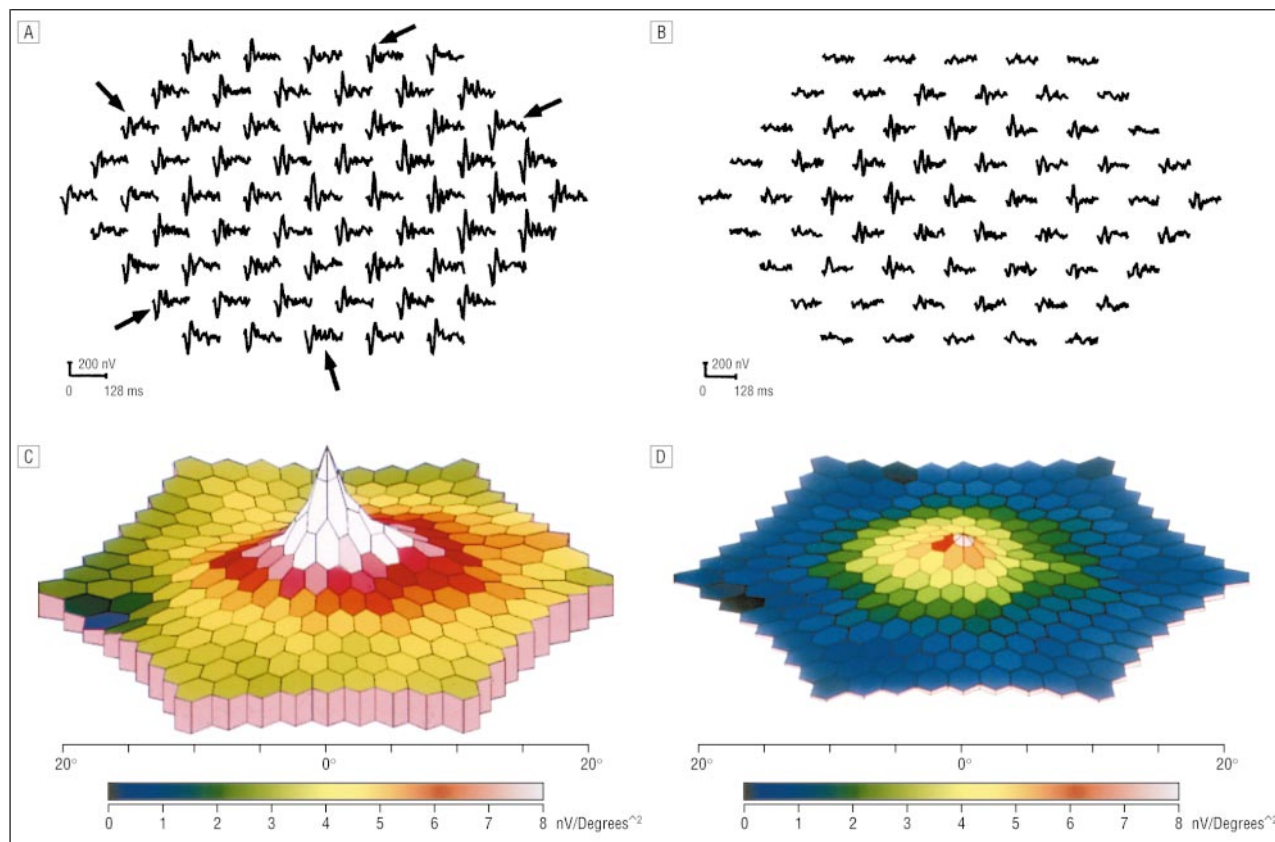


Figure 2. The multifocal electroretinogram of the patient receiving treatment with vigabatrin and the patient with retinitis pigmentosa (left eyes) shown in Figure 1. A, Trace array of the patient receiving treatment with vigabatrin showing the 61 local responses representing the cone activity within the central 50° of visual angle. The change of wave form is marked by arrows (see "Report of a Case" section for further details). B, Trace array of the patient with retinitis pigmentosa showing the typical decrease of amplitude and increase of implicit time in the affected regions. C, A 3-D representation (scalar product) of the data from part A. The central peak corresponds to the high cone density of the fovea; the blind spot is visible on the left. D, A 3-D representation of the data for part B. Note the peripheral loss of response density.

tion associated with vigabatrin medication.

Klaus Ruether, MD
 Tamara Pung, MD
 Ulrich Kellner, MD
 Bettina Schmitz
 Christian Hartmann, MD, PhD
 Berlin, Germany
 Mathias Seeliger, MD
 Tuebingen, Germany

Corresponding author: Klaus Ruether, MD, Charité-Virchow Augenklinik, Augustenburger Platz 1, 13353 Berlin, Germany (e-mail: ruether@ukrv.de).

1. Bayer AU, Thiel H-J, Zrenner E, Paulus W, Ried S, Schmidt D: Disorders of color perception and increased glare sensitivity in phenytoin and carbamazepine therapy: ocular side effects of anticonvulsants. *Nervenarzt*. 1995; 66:89-96.
2. Eke T, Talbot JF, Lawden MC: Severe persistent visual field constriction associated with vig-

abatrin [with letters of correspondence appearing in *BMJ*. 1997;314:1693-1695]. *BMJ*. 1997; 314:180-181.

3. Graham D. Neuropathology of vigabatrin. *Br J Clin Pharmacol*. 1979;27(suppl 1):43-53.
4. Seeliger M, Kretschmann U, Apfelstedt-Sylla E, Ruether K, Zrenner E. Multifocal electroretinography in Retinitis pigmentosa. *Am J Ophthalmol*. 1997;125:214-226.
5. Perucca E. The clinical pharmacology of the new antiepileptic drugs. *Pharmacol Res*. 1993;28:89-106.
6. Kalloniatis M. Amino acids in neurotransmission and disease. *J Am Optom Assoc*. 1995; 66: 750-757.